

# Comparison of Er:YAG Laser and Surgical Drill for Osteotomy in Oral Surgery: An Experimental Study

*Dragana Gabrić Pandurić, PhD, DMD,\* Ivona Bago, DMD,†  
Davor Katanec, PhD, MS, DMD,‡ Janez Žabkar, PhD,§  
Ivana Miletić, PhD, MS, DMD,|| and Ivica Anić, PhD, MS, DMD¶*

**Purpose:** High-energy lasers have been proposed as an alternative to the conventional surgical drill in oral and maxillofacial surgery. The aims of this study were to compare thermal changes of the bone surface, procedure time, and volume of the removed bone after drilling with an erbium (Er):yttrium-aluminum-garnet (YAG) laser versus a low-speed surgical drill. The bone sections were observed under light microscopy and examined histologically.

**Material and Methods:** Thirty bone blocks were prepared from porcine ribs. On each block 2 holes (tunnel preparations) were performed using a low-speed, 1.0-mm-wide, surgical pilot drill and an Er:YAG laser (pulse energy, 1,000 mJ; pulse duration, 300  $\mu$ s; frequency, 20 Hz). The temperature induced by the preparation techniques was measured using an infrared camera. The removed bone volume was calculated by a modified mathematical algorithm. The time required for the preparation was measured with a digital stopwatch and a time-measurement instrument integrated within the computer program. The cortical and spongiose surfaces of the specimens were examined microscopically and histologically under a light microscope with a high-resolution camera.

**Results:** The Er:YAG laser removed significantly more bone tissue than the drill ( $P < .01$ ) in a significantly shorter time ( $P < .01$ ). The temperature was statistically lower during the laser preparation ( $P < .01$ ). Cavities prepared with the laser were regular with clear sharp edges and knifelike cuts. In the drill group, the preparations exhibited irregular edges full of bone fragments and fiberlike debris. Histologic examination of the laser sides showed a 30- $\mu$ m-thick altered sublayer. The tissue in the drill group was covered with a smear layer without any alterations.

**Conclusions:** The Er:YAG laser produced preparations with regular and sharp edges, without bone fragments and debris, in a shorter time, and with less generated heat. Thermal alterations in the treated surface were minimal.

© 2012 American Association of Oral and Maxillofacial Surgeons  
*J Oral Maxillofac Surg* 70:2515-2521, 2012

The disadvantages of the conventional drill, which is the most frequently used system for osteotomies and ostectomies in oral and maxillofacial surgery,<sup>1</sup> are the increase of the focal temperature of regions undergoing the procedure, the deposition of metal shavings, and bacterial decontamination.<sup>2-4</sup> Although the instru-

ments are fitted with an internal cooling system, it is not possible to prevent thermal damage completely.<sup>5</sup> Allan et al<sup>6</sup> observed a necrotic surface zone after bone treatment with mechanically rotating instruments. Injury of the bone cells caused by the frictional heat generated during the mechanical preparation

Received from the School of Dental Medicine, University of Zagreb, Zagreb, Croatia.

\*Department of Oral Surgery.

†Department of Endodontics and Restorative Dentistry.

‡Department of Oral Surgery.

§Fotona dd, Ljubljana, Slovenia.

||Department of Endodontics and Restorative Dentistry.

¶Department of Endodontics and Restorative Dentistry.

This study was performed and financed within the research project Experimental and Clinical Endodontology (065-0650444-

0418) and approved by the Ministry of Science, Education, and Sport of the Republic of Croatia.

Address correspondence and reprint requests to Dr Bago: Department of Endodontics and Restorative Dentistry, School of Dental Medicine, University of Zagreb, Gundulićeva 5, 10000 Zagreb, Croatia; e-mail: bago@sfzg.hr

© 2012 American Association of Oral and Maxillofacial Surgeons

0278-2391/12/7011-0\$36.00/0

<http://dx.doi.org/10.1016/j.joms.2012.06.192>

may delay or even prevent healing.<sup>7</sup> In addition, the vibrations generated during the surgical procedures with mechanically rotating instruments disturb patients.<sup>8,9</sup>

Over the past several decades, different types of high-energy lasers have been investigated in bone surgery.<sup>10,11</sup> Among them, the erbium (Er):yttrium-aluminum-garnet (YAG) laser, emitting at a wavelength of  $2.94\ \mu\text{m}$ , possesses properties suitable for clinical bone surgery.<sup>12</sup> It is well absorbed in water and hydroxyapatite, causing a photothermal reaction and photoablation.<sup>13</sup> Extensive heating of the bone and surrounding tissues during irradiation has been overcome by the pulse-mode laser and the water spray,<sup>12,14</sup> ensuring good clinical results without any impairment to wound healing.<sup>15</sup> Histologic and electronic microscopic evaluations of the efficacy of the Er:YAG laser have shown minimal thermal damage of the bone, precise cutting, rapid osseous healing, and osteoinduction.<sup>16,17</sup> Compared with conventional mechanical drills and saws, it provides a noncontact and low-vibration intervention, a high bactericidal and detoxification effect, less traumatization, and decreased bleeding. Moreover, by using a laser, it is possible to remove bone tissue from places that are difficult to access by conventional methods; and it is less invasive.<sup>18,19</sup> However, the routine application of the Er:YAG laser has not been established in clinical practice. Some researchers have documented longer periods for an osteotomy compared with mechanical drills.<sup>15,20</sup> Moreover, an inability to control the depth of the cut may complicate the procedure in an area with an unknown size around the focus,<sup>21</sup> so the depth control is usually intuitive.<sup>8,22</sup> This problem is partly solved by the recently developed assistance systems for a precise intraoperative realization of preoperative planning.<sup>8,22-24</sup> Such navigated laser surgery is especially advantageous for an inexperienced surgeon because the operating technique is safer and easier compared with an oscillating saw.<sup>25</sup>

The purpose of this study was to compare the Er:YAG laser with a surgical drill in osteotomy based on specific physical and histologic evaluations: 1) thermal changes of the bone surface, 2) the time required for the preparation, and 3) the volume of the removed bone during the procedure with the Er:YAG laser versus the low-speed surgical pilot drill. The alterations in bone tissue after Er:YAG irradiation and a low-speed pilot drill were analyzed by light microscopy and histology. The null hypothesis was that there would be no difference between the Er:YAG laser and the surgical drill in the osteotomy.

## Materials and Methods

### SAMPLE PREPARATION

The research protocol was approved by the local ethics committee. The experimental study was performed on freshly harvested sternums from porcine ribs, which were split into 2 halves by saggital osteotomy. A water-cooled slow-speed diamond disk (Isomet 1000; Buehler International, Inc, Lake Bluff, IL), set at 250 rpm with a 100-g load, was used to split each half of the rib into equal segments ( $2.0 \times 1.0 \times 0.5\ \text{cm}$ ) with approximately the same thickness for the cortical and spongiose parts. The study sample consisted of 30 bone blocks that were stored in 0.1% thymol solution until use to decrease bacterial growth and prevent dehydration of the samples. The thickness of the blocks was  $4.6 \pm 0.7\ \text{mm}$ , including the cortical ( $1.3 \pm 0.4\ \text{mm}$ ) and spongiose ( $3.3 \pm 0.6\ \text{mm}$ ) parts. Before the experimental procedures, the samples were dried with compressed air and adjusted to room temperature.

### EXPERIMENTAL PROCEDURES

The bone blocks were divided into 2 equal parts with a line parallel to the shorter side of the block. Two holes were created in each bone block, 1 at each part, by using a pilot drill and an Er:YAG laser. The holes spanned the full thickness of the block (tunnel preparation) to simulate the preparation for the fixation screw site.

The first hole was prepared using a low-speed handpiece (1,500 rpm) with a 1.0-mm-wide pilot-type stainless steel drill (Screw System, Meisinger, Neuss, Germany) under constant saline irrigation.

At a distance of 7 mm from the first hole, another hole was prepared with the short pulse Er:YAG laser and an RO<sub>2</sub>-C handpiece (AT Fidelis; Fotona dd, Ljubljana, Slovenia) under constant cooling with a water spray (30 mL/min). The Er:YAG laser operated in noncontact mode at a distance of 7 mm from the bone surface. The laser parameters were a  $\lambda$  value equal to  $2.94\ \mu\text{m}$ , 20-W power, 1,000-mJ pulse energy, 20-Hz frequency, 300- $\mu\text{s}$  pulse duration, and 0.9-mm spot size.

During the preparations, an articulated arm delivery system of the laser and a low-speed handpiece set were fixed. The bone plates were fixed with a clamp. To ensure the blinded character of the study, the bone sections and hole preparations were performed by an expert in oral-maxillofacial surgery (D.P.G.). Another operator (I.B.) marked the specimens before the preparations and performed all the measurements. Biosecurity standards to protect the personnel were followed.

### TEMPERATURE MEASUREMENTS

The temperature profiles induced by the laser and drilling tool were measured using an infrared camera (ThermoCAM P45; FLIR Systems, Danderyd, Sweden) during the entire interval of the bone exposure and preparation period. The thermal camera was connected directly to the computer. The lens was oriented toward the samples, approximately 20 cm beneath the upper cortical surface of the bone plates, and fixed during the recording period. The temperature changes of the surface were measured and reproduced on the display as a diagram and a color image.

### VOLUME MEASUREMENTS

The volume of the removed bone tissue during the tunnel preparations was calculated by a modified mathematical algorithm based on the incomplete bevel volume formula ( $V = \pi \times v/3[R^2 + r^2 + R \times r]$ ) ( $V$  = bevel volume,  $v$  = thickness of a sample,  $R$  = radius of a greater cross section area,  $r$  = radius of a smaller cross section area). The largest diameter of the hole, including the cortical and spongiose parts, and the entry and exit diameters of the tunnel preparation were measured using a custom-made triangular laser-based profile meter (Fotona dd) with resolutions of 5, 20, and 5  $\mu\text{m}$  on the  $x$ ,  $y$ , and  $z$  axes, respectively, and with 5% precision. It was connected directly to the computer, digital caliper (Caliper-Digital; Salvin Dental Specialties, Inc, Charlotte, NC), and a light microscope (BX 51; Olympus, Tokyo, Japan) with  $\times 10$  magnification and an integrated measurement scale.

### TIME MEASUREMENTS

The time required for the tunnel preparation using the laser and the pilot drill was measured with a digital stopwatch (RF43379; Richforth Electronics Company, Fujian, China) and with a time-measurement instrument, which was integrated within the computer program for the thermal camera (ThermaCAM Researcher Pro 2.8 SR-2, FLIR Systems).

### LIGHT MICROSCOPIC AND HISTOLOGIC EXAMINATIONS

After the preparations, the specimens were stored in 10% buffered formalin until the histologic examination. The cortical and spongiose surfaces of the tunnel preparation were analyzed under a light microscopic camera at  $\times 10$  magnification (BX 51; Olympus) and a high-resolution camera for the clinical recording (D700; Nikon, Tokyo, Japan). For the histologic examination, the samples were decalcified in Osteosoft (Merck KGaA, Darmstadt, Germany; pH 7 to 7.3) for 50 days. The samples were dehydrated in an Shandon Excelsior ES™ (Thermo Scientific, Lough-

borough, UK) tissue processor using the traditional reagents: serial concentrations of ethanol, xylol, and paraffin (Merck KGaA). After the dehydration protocol, the specimens were inserted in paraffin blocks (Merck KGaA), trimmed, and cut sagittally through the center of the tunnel preparation using an electric, round, microcutting machine (Shandon Finesse Microtome, Thermo Scientific, Waltham, MA). The 3- $\mu\text{m}$ -thick histologic sections were stained with hematoxylin and eosin (Merck KGaA) and observed under a light microscope at  $\times 40$  and  $\times 100$  magnifications. Photomicrographs were taken, and the observation was performed by a trained examiner.

### STATISTICAL ANALYSIS

The nonparametric Wilcoxon signed-rank test was applied to test the equality of the sample's medians between the laser and drill groups. Then, all the parameters (volume, time, thickness of bone plate, thickness of cortical and spongiose parts, starting and final surface temperatures, difference between starting and final surface temperatures, maximum temperature level) were analyzed separately using the linear regression model and the Spearman rank correlation coefficient.

## Results

### QUANTITATIVE ANALYSIS

Table 1 presents the measured parameters for the laser and surgical drill groups: the volume of the removed bone, the preparation time, and the temperature changes during the preparation. There was a significant statistical difference ( $P < .001$ ) between the Er:YAG laser and the surgical pilot drill for all measured parameters except the temperature interval ( $P = .742$ ). The maximum temperature level in the laser group was directly related to the thickness of the bone plate ( $P = .001$ ) and the starting surface temperature ( $P = .065$ ). In the drill group, there were no statistically significant relations between the measured parameters ( $P > .05$ ).

### LIGHT MICROSCOPIC OBSERVATION

In the laser group, all cavities exhibited a regular shape with sharp edges and smooth cuts and regular borders on the cortical side. There were no signs of thermal damage (Fig 1A). In the drill group, irregular edges and an irregular shape were observed on the cortical surface of the cavity. The edges were filled with bone fragments and fiberlike debris. There were no signs of thermal damage (Fig 1B). On the spongiose side, irregular edges and borders of the cavitations were observed after using the Er:YAG laser and the drill (Fig 2).

**Table 1. SUMMARY OF QUANTITATIVE DATA MEASURED AFTER PREPARATION WITH THE ER:YAG LASER AND SURGICAL DRILL**

	Diameter of Hole (mm)		Removed Bone Tissue ( $\mu\text{L}$ )	Time (s)	Starting Temperature ( $^{\circ}\text{C}$ )	Final Temperature ( $^{\circ}\text{C}$ )	Maximum Temperature ( $^{\circ}\text{C}$ )	Temperature Interval ( $^{\circ}\text{C}$ )
	Cortical Surface	Spongiose Surface						
Laser	$2.0 \pm 0.4$	$1.2 \pm 0.2$	$9.7 \pm 3.6$	$3.1 \pm 0.7$	$21.2 \pm 1.5$	$26.8 \pm 0.9$	$68.7 \pm 22.5$	$6.1 \pm 0.8$
Surgical drill	$1.0 \pm 0.1$	$0.9 \pm 0.2$	$3.7 \pm 1.1$	$17.9 \pm 9.7$	$24.3 \pm 0.7$	$30.6 \pm 2.6$	$31.4 \pm 2.1$	$6.3 \pm 2.5$
<i>P</i>	<.001	<.001	<.001	<.001	<.001	<.001	<.001	$6.3 \pm 2.5$



Note: P values are presented as mean  $\pm$  standard deviation.

Pandurić et al. Er:YAG Laser versus Surgical Drill. *J Oral Maxillofac Surg* 2012.

### HISTOLOGIC EXAMINATION



The margins of the osteotomy performed with the laser showed a 30- $\mu\text{m}$ -thick altered layer (Fig 3). The superficial, thin, affected layer with irregular borders was composed of 2 sublayers: a lightly stained superficial layer with signs of carbonization and amorphous

structures and a darkly stained underlying layer with minimal thermal damage. Empty osteocytic lacunae could be observed approximately 30  $\mu\text{m}$  from the irradiated surface. The drill sites did not present an altered layer or signs of thermal damage (carbonization or melting). The treated surface was covered with a smear layer (Fig 4).



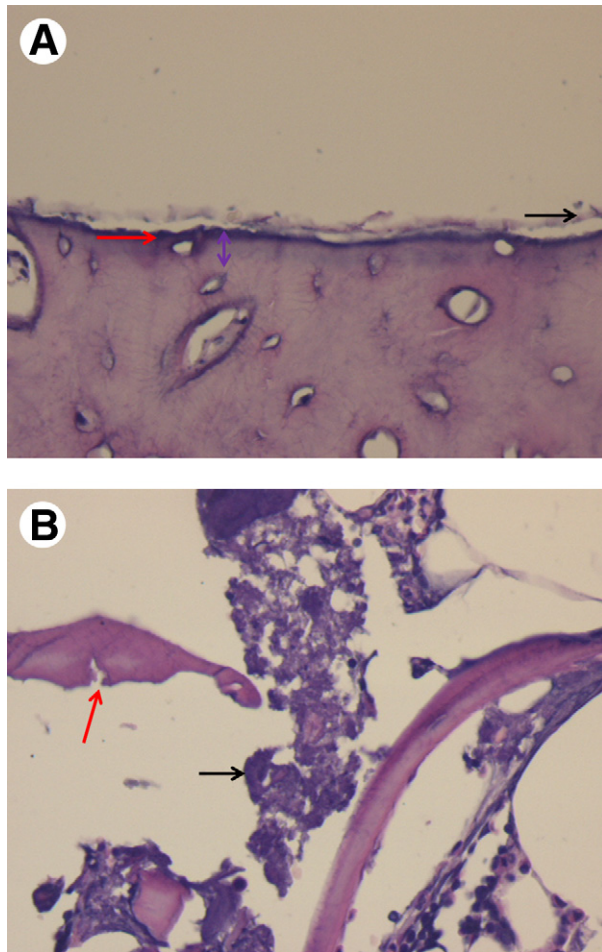
**FIGURE 1.** Cortical appearance (magnification,  $\times 10$ ): A, laser preparation; B, drill preparation.

Pandurić et al. Er:YAG Laser versus Surgical Drill. *J Oral Maxillofac Surg* 2012.



**FIGURE 2.** Spongiose appearance (magnification,  $\times 10$ ): A, laser preparation; B, drill preparation.

Pandurić et al. Er:YAG Laser versus Surgical Drill. *J Oral Maxillofac Surg* 2012.



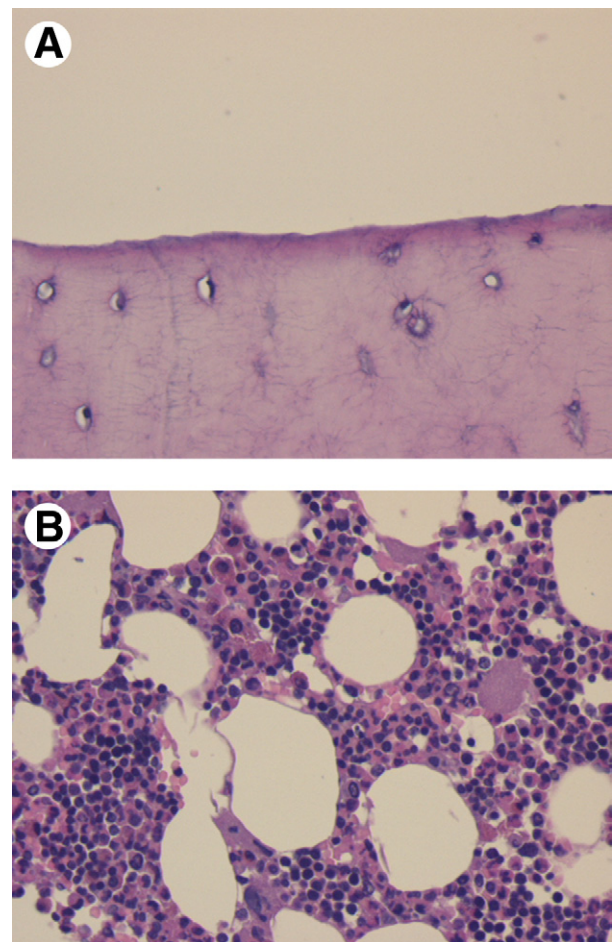
**FIGURE 3.** Representative photomicrographs of histologic sections of the irradiation sides. *A*, The cortical side (magnification,  $\times 40$ ) shows a layer of carbonization (red arrow), an amorphous layer (black arrow), and a deeper layer with thermal alteration (purple arrow). *B*, The spongiosa side (magnification,  $\times 100$ ) shows a coagulation of collagen (black arrow) and amorphous alterations in the deeper layers (red arrow).

Pandurić et al. *Er:YAG Laser versus Surgical Drill*. *J Oral Maxillofac Surg* 2012.

## Discussion

The present *ex vivo* study compared the efficiency of the Er:YAG laser with the conventional pilot drill used for the preparation of holes for fixation screws. For that reason, the volume of the removed bone, the required time, and the temperature generated were analyzed. The efficiency of the techniques was evaluated in bone blocks prepared from the sternums of porcine ribs, with approximately the same thickness for the cortical and spongiosa parts. The idea was to simulate the height and width of the intraoral autologous bone blocks commonly used in dental implantology ( $2.0 \times 1.0 \times 0.5$  cm). Animal bone samples (porcine and bovine) have been used in previous studies for an evaluation of the laser effect in oral and maxillofacial surgery.<sup>8,26</sup>

The results showed an excellent cutting efficiency using the Er:YAG laser without any extensive time requirement. The overall mean time for the Er:YAG was 3.1 seconds, whereas that for the surgical drill was 17.9 seconds. Moreover, during these periods, the Er:YAG laser removed an almost 3 times larger volume of bone tissue than the drill. These observations are in contrast with previous studies that claimed that the time required for complete osteotomy was a limiting factor for the application of the laser in oral and maxillofacial surgical clinical practice.<sup>17,21,27,28</sup> It is difficult to measure the exact time for harvesting a bone graft in the clinical situation because it depends on not only the bone quality and surgical technique but also the surgical site, where blood and water may influence the attenuation of the laser beam.<sup>17</sup> The preparation of the holes for the fixation screws is accomplished outside the oral cavity so, when analyzing the surgical techniques, the



**FIGURE 4.** Representative photomicrographs of the histologic sections of the sides treated with the drill: *A*, cortical side with a smear layer (magnification,  $\times 40$ ); *B*, spongiosa side (magnification,  $\times 100$ ).

Pandurić et al. *Er:YAG Laser versus Surgical Drill*. *J Oral Maxillofac Surg* 2012.

bone quality and the laser settings such as pulse duration, pulse energy, and frequency have to be considered.<sup>15,29</sup> Papadaki et al<sup>26</sup> compared different energies per pulse (500, 1,000, 1,500, and 2,000 mJ) for osteotomy in a large animal model and concluded the osteotomy was performed faster as the energy per pulse increased. The high-pulse energy (1,000 mJ) and high frequency (20 Hz) of the Er:YAG laser used in the present study are the likely reasons for the very short time required for the preparation. Furthermore, the Er:YAG laser produced an exact cutting surface with regular borders on the cortical side, whereas the pilot drill produced irregular edges filled with bone fragments and fiberlike debris. These observations are in accord with previous animal experiments evaluating the effect of the Er:YAG laser on the hard dental and vital osseous tissues.<sup>30-32</sup> Papadaki et al<sup>26</sup> and Romeo et al<sup>32</sup> found a smooth cut after the use of very high-pulse energies and numerous bone fragments and debris after the use of rotating instruments. Fragments and fiberlike debris found on the bone surface after using a mechanical pilot drill may be a risk for potential infection.<sup>17</sup> On the other side, the lack of a smear layer may increase the adhesion of blood elements at the start of the healing process.<sup>16</sup> Stübinger et al<sup>17</sup> macroscopically observed an equally rough and craggy bone surface after osteotomy performed with a conventional drill as with an Er:YAG laser. No additional bone dust or particles were generated during the Er:YAG laser irradiation, thus decreasing the risk for a potential infection caused by bony particles dispersed within the periosteum.<sup>17</sup>

The precision of the pulse Er:YAG laser in bone surgery is explained by its high absorption coefficient in water and its interaction with bone tissue. The Er:YAG laser beam has high energy at its center, whereas the energy is lower at the outer region of the beam. Thus, the beam efficiently ablates the tissue at its center by thermal vaporization and microexplosions of the tissue. Away from its center, the energy is lower and insufficient for tissue ablation, causing charring of the bone tissue as a result of a cumulative heat deposition.<sup>33</sup> Therefore, the histologic analysis showed some thermal damage at the margins of the osteotomies performed using the Er:YAG laser (500 mJ, 10 Hz).<sup>19</sup> The present study showed similar findings, where the use of the Er:YAG laser (1,000 mJ, 20 Hz) resulted in an approximately 30- $\mu$ m-thick altered layer on the margins of the osteotomy. The layer was composed of a superficial part without clear structures and an underlying layer with minimal thermal damage. The drill sites were covered with the smear layer. Similarly, Sasaki et al<sup>16</sup> analyzed the ultrastructure of bone tissue (parietal bones of rats) treated with the Er:YAG laser for 2 to 3 seconds with a water coolant and observed minimal changes of 13.2- to

30- $\mu$ m thickness without severe thermal damage. Histologically, the changed layer consisted of a lightly stained superficial layer without defined structures and a deep, less affected layer. They also reported that the affected layer was basically nontoxic, although transmission electron microscopy showed minor compositional changes with a major loss of the organic components and a minor loss of the inorganic components.<sup>16</sup> This altered layer is believed to be harmless with regard to bone healing.<sup>34</sup> In a study by Yoshino et al,<sup>34</sup> Er:YAG irradiation (115 mJ/pulse, 10 Hz, noncontact mode) during 3 seconds without a water coolant created the affected layer, which did not inhibit cell migration and proliferation, and the direct deposition of new bone on the lased surface was generally observed. In the present study, light microscopic analysis did not show any signs of thermal damage after testing the 2 techniques. Stübinger et al<sup>17</sup> and Papadaki et al<sup>26</sup> also did not observe macroscopically any surface alterations after the use of the Er:YAG laser.

The pulse laser systems have been found to have the lowest risk of scarring and unwanted thermal diffusion.<sup>14,15</sup> The absence of thermal alterations of tissue caused by the pilot drill is probably due to the low speed and constant irrigation, as explained in a study by De Mello et al.<sup>18</sup> Eriksson and Albrektsson<sup>35</sup> described the critical temperature for bone to be 47°C and noted that a temperature increase from 44°C to 47°C may lead to tissue necrosis. In this research, the average temperature did not increase above 32°C during the preparation with the 2 techniques. The maximum temperature of 68.7°C measured during Er:YAG irradiation is related to the temperature necessary for the ablation of tissue and, according to the histologic examination, did not cause thermal damage to the surrounding tissue.

In the present study, the Er:YAG laser showed some advantages during the preparation of holes for fixation screws compared with the surgical drill, such as a shorter preparation time, a lower heat generation, the sharp edges of the holes without bone fragments, and the smear layer on the surface. The thermal alterations of the bone tissue produced by Er:YAG laser irradiation with a water coolant were minimal.

#### *Acknowledgments*

The authors acknowledge Fotona dd, Ljubljana, Slovenia and the Institute for Physics, Zagreb, Croatia for support and assistance.

#### **References**

1. Martins GL, Puricelli E, Baraldi CE, et al: Bone healing after bur and Er:YAG laser osteotomies. *J Oral Maxillofac Surg* 69:1214, 2011
2. Barone CM, Jimenez DF, Yule GJ, et al: Analysis of bone formation after cranial osteotomies with a high-speed drill. *J Craniofac Surg* 8:466, 1997

3. Kerawala CJ, Martin IC, Allan W, et al: The effects of operator technique and bur design on temperature during osseous preparation for osteosynthesis self-tapping screws. *Oral Surg Oral Med Oral Pathol Oral Radiol Endod* 88:145, 1999
4. Kondo S, Okada Y, Iseki H, et al: Thermological study of drilling bone tissue with a high-speed drill. *Neurosurgery* 46:1162, 2000
5. Misch CM: Comparison of intraoral donor sites for onlay grafting prior to implant placement. *Int J Oral Maxillofac Implants* 12:767, 1997
6. Allan W, Williams ED, Kerawala CJ: Effects of repeated drill use on temperature of bone during preparation for osteosynthesis self-tapping screws. *Br J Oral Maxillofac Surg* 43:314, 2005
7. Albrektsson T, Linder L: Intravital, long-term follow up of autologous, experimental bone grafts. *Arch Orthop Trauma Surg* 189:1981, 1998
8. Hohlweg-Majert B, Deppe H, Metzger MC, et al: Bone treatment laser-navigated surgery. *Lasers Med Sci* 25:67, 2010
9. Anic I, Miletic I, Krmek SJ, et al: Vibrations produced during erbium:yttrium-aluminum-garnet laser irradiation. *Lasers Med Sci* 24:697, 2009
10. Bhatta N, Isaacson K, Bhatta KM, et al: Comparative study of different laser systems. *Fertil Steril* 61:581, 1994
11. Friesen LR, Cobb CM, Rapley JW, et al: Laser irradiation of bone: II. Healing response following treatment by CO<sub>2</sub> and Nd:YAG lasers. *J Periodontol* 70:75, 1999
12. Walsh JT Jr, Deutsch TF: Er:YAG laser ablation of tissue: Measurement of ablation rates. *Lasers Surg Med* 9:327, 1989
13. Nelson JS, Orenstein A, Liaw LH, et al: Mid-infrared erbium: YAG laser ablation of bone: The effect of laser osteotomy on bone healing. *Lasers Surg Med* 9:362, 1989
14. Nanni C: Complications of laser surgery. *Dermatol Clin* 15:521, 1997
15. Zitzmann NU, Schärer P, Marinello CP: Long-term results of implants treated with guided bone regeneration: A 5-year prospective study. *Int J Oral Maxillofac Implants* 16:355, 2001
16. Sasaki KM, Aoki A, Ichinose S, et al: Ultrastructural analysis of bone tissue irradiated by Er:YAG laser. *Lasers Surg Med* 31:322, 2002
17. Stübinger S, Landes C, Seitz O, et al: Er:YAG laser osteotomy for intraoral bone grafting procedures: A case series with a fiber-optic delivery system. *J Periodontol* 78:2389, 2007
18. De Mello ED, Pagnoncelli RM, Munin E, et al: Comparative histological analysis of bone healing of standardized bone defects performed with the Er:YAG laser and steel burs. *Lasers Med Sci* 23:253, 2008
19. Eyrich GK: Laser-osteotomy induced changes in bone. *Med Laser Appl* 20:25, 2005
20. Rupprecht S, Tangermann K, Kessler P, et al: Er:YAG laser osteotomy directed by sensor controlled systems. *J Craniomaxillofac Surg* 31:337, 2003
21. Rupprecht S, Tangermann-Gerk K, Wiltfang J, et al: Sensor-based laser ablation for tissue specific cutting: An experimental study. *Lasers Med Sci* 19:81, 2004
22. Davidson SR, James DF: Drilling in bone: Modeling heat generation and temperature distribution. *J Biomech Eng* 125:305, 2003
23. Stelnicki EJ, Hollier L, Lee C, et al: Distraction osteogenesis of costochondral bone grafts in the mandible. *Plast Reconstr Surg* 109:925, 2002
24. Ayman A, Shekar P: The use of costochondral grafts in the management of temporomandibular joint ankylosis. *Plast Reconstr Surg* 27:73, 2003
25. Stopp S, Deppe H, Lueth T: A new concept for navigated laser surgery. *Lasers Med Sci* 23:261, 2008
26. Papadaki M, Doukas A, Farinelli WA, et al: Vertical ramus osteotomy with Er:YAG laser: A feasibility study. *Int J Oral Maxillofac Surg* 36:1193, 2007
27. Stübinger S, von Rechenberg B, Zeilhofer HF, et al: Er:YAG laser osteotomy for removal of impacted teeth: Clinical comparison of two techniques. *Lasers Surg Med* 39:583, 2007
28. Stübinger S, Nuss K, Landes C, et al: Harvesting of intraoral autogenous block grafts from the chin and ramus region: Preliminary results with a variable square pulse Er:YAG laser. *Lasers Surg Med* 40:312, 2008
29. Fried NM, Fried D: Comparison of Er:YAG and 9.6-microm TE CO<sub>2</sub> lasers for ablation of skull tissue. *Lasers Surg Med* 28:335, 2001
30. Harashima T, Kinoshita J, Kimura Y, et al: Morphological comparative study on ablation of dental hard tissues at cavity preparation by Er:YAG and Er,Cr:YSSG lasers. *Photomed Laser Surg* 23:52, 2005
31. Kimura Y, Yu DG, Fujita A, et al: Effects of erbium, chromium YSSG laser. *J Calif Dent Assoc* 72:1178, 2001
32. Romeo U, Del Vecchio A, Palaia G, et al: Bone damage induced by different cutting instruments—An in vitro study. *Braz Dent J* 20:162, 2009
33. Sasaki KM, Aoki A, Ichinose S, et al: Scanning electron microscopy and Fourier transformed infrared spectroscopy analysis of bone removal using Er:YAG and CO<sub>2</sub> lasers. *J Periodontol* 73:643, 2002
34. Yoshino T, Aoki A, Oda S, et al: Long-term histologic analysis of bone tissue alteration and healing following Er:YAG laser irradiation compared to electrosurgery. *J Periodontol* 80:82, 2009
35. Eriksson RA, Albrektsson T: The effect of heat on bone regeneration: An experimental study in the rabbit using the bone growth chamber. *J Oral Maxillofac Surg* 42:705, 1984