

Navigare necesse est. Possible reconstruction of a maritime-activities related occupation based on the presence of auditory exostoses in an individual from the Roman period city of *Iader*

Mario Novak¹, Timka Alihodžić², Mario Šlaus¹

¹Anthropological Centre, Croatian Academy of Sciences and Arts, 10 000 Zagreb, Croatia

²Archaeological Museum Zadar, 23 000 Zadar, Croatia

ABSTRACT: Large bilateral auditory exostoses were recorded in the skeleton of an adult male buried in the Roman period necropolis of Zadar-Relja (the Roman colony of *Iader*) in southern Croatia. As the occurrence of auditory exostoses in both past and modern populations has been correlated with prolonged exposure to cold water, the authors propose that during his lifetime this individual performed activities requiring frequent contact with cold water for an extended period of time. Apart from auditory exostoses, this individual also exhibits other pathological changes including pronounced skeletal robustness, benign cortical defects at the insertion of the pectoralis major muscles on both humeri and at the attachment sites of the costo-clavicular ligaments on both clavicles, and vertebral osteoarthritis in the cervical and thoracic vertebrae. The most plausible explanation for all these changes is that this person spent most of his life working aboard a sea vessel as a sailor, boat builder or fisherman, and whose duties included frequent and intensive use of oars. This observation is based on the geographic and climatic location of Zadar, the described skeletal changes, the archaeological context of the site, recovered material artifacts and written historic sources and comparisons with similar studies.

KEY WORDS: auditory exostoses, musculoskeletal stress markers, maritime activities, Roman period, Zadar

Introduction

Exostoses of the external auditory canal (alternatively; auditory torus, auditory exostosis, *torus acusticus* or *torus tympanicus*) are benign bone anomalies generally located on the floor of the external auditory canal that typically occur bilaterally.

They can be spheroid or oval, appearing like a pea or a small bean, and they can grow to completely block the auditory canal (Kennedy 1986).

Until recently, the cause of auditory exostoses was thought to be genetic (Blake 1880; Berry 1975), but most authors

currently believe that the occurrence of auditory exostoses is primarily caused by environmental factors (Kennedy, 1986; Standen et al. 1997; Chaplin and Stewart 1998; Velasco-Vazquez et al. 2000; Kroon et al. 2002). Among these, activities associated with continuous exposure to cold water below 19°C, such as diving, aquatic sports, and ocean navigation are considered the most important factors in the development of this anomaly (DiBartolomeo 1979; Filipo et al. 1982; Kennedy 1986). In the past several decades the occurrence and frequency of auditory exostoses has been studied in numerous archaeological skeletal samples from different chronological periods and geographic locations (Ascenzi and Balistreri 1975; Kennedy 1986; Frayer 1988; Manzi et al. 1991; Sakalinskas and Jankauskas 1993; Standen et al. 1997; Gerszten et al. 1998; Velasco-Vazquez et al. 2000; Okumura et al. 2007; Agelarakis and Serpanos 2010; Miladinović-Radmilović 2010).

The most important analysis of a proposed correlation between continuous exposure to cold water and auditory exostoses occurrence in populations from different geographic regions was most likely the one conducted by Kennedy (1986). She hypothesized that lower frequencies of auditory exostoses could be expected in polar and sub-polar regions due to the avoidance of cold water because of the risk of hypothermia, and in tropical regions where people were accustomed to warmer water, rarely below 21°C (Kennedy 1986). She also found that populations living between 30° and 45° north and south latitudes, where water temperatures are usually below 19°C, exhibited higher frequencies of auditory exostoses. These elevated frequencies of auditory exostoses also correlated with intensive exploitation of marine and/or

freshwater resources through diving and other aquatic activities (Kennedy 1986).

Today, auditory exostoses are common in individuals who practise aquatic sports, and the frequency of this trait and the degree of canal obstruction are positively correlated with the intensity and length of time involved in aquatic sports activities (Kroon et al. 2002). Several archaeological and clinical studies (Hrdlička 1935; DiBartolomeo 1979; Manzi et al. 1991) identified either an absence, or only occasional occurrence, of auditory exostoses in individuals less than 20 years of age, thus strongly implying that this is an acquired condition (Aufderheide and Rodríguez-Martín 1998).

In this paper, we report the presence of exostoses in the external auditory canal of an adult male recovered from grave 7 in the Roman period necropolis of Zadar-Relja in Dalmatia, Croatia. In addition, precise reconstruction of the habitual activities of this individual is attempted, based on the results of a comprehensive bio-archaeological analysis of all recorded skeletal pathological changes, together with recovered material artifacts and available historic sources.

Material and methods

Archaeological context

The modern city of Zadar is situated on the eastern Adriatic coast in Croatia (Fig. 1). Large-scale rescue archaeological excavations at the location of the central necropolis of the Roman period colony of *Iader* were carried out between 1989 and 2009 in the Relja district of the city of Zadar, uncovering over 2,000 graves. Most of these excavations were led by the Archaeological Museum Zadar. 543

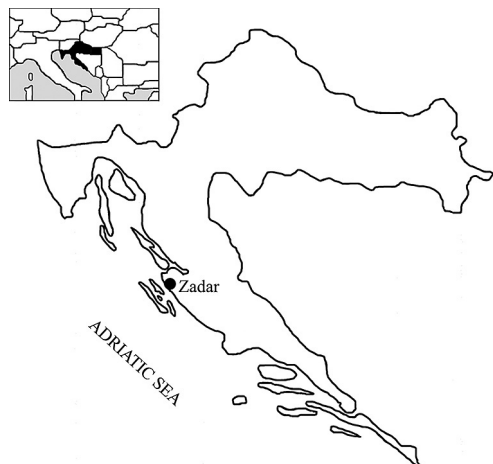


Fig. 1. Map of Croatia with the geographical location of Zadar

graves, including both inhumations and incinerations, were excavated at the location of the Relja Shopping centre, during phase 2 between 2005 and 2009. Based on recovered artifacts, the burials in this location are dated between the 1st and the 4th centuries AD.

Grave 7, excavated in 2005, was an inhumation burial in plain ground with no grave architecture. Fragments of Roman *tegulae* and amorphous stones were deposited above the skeleton, while natural bedrock was located on the north side of the individual's lower extremities. The skeleton was in a flexed position, on its right side, lying in a NE–SW direction (Fig. 2), with bronze wire forming an ankle bracelet around the right ankle.

It is important to note here that in addition to Roman period burials, the Relja site also contained several flexed inhumation burials attributed to Liburnian Iron Age individuals who inhabited this region before the Romans. Analyses of grave artifacts, particularly the very characteristic *fibulae*, suggest these burials

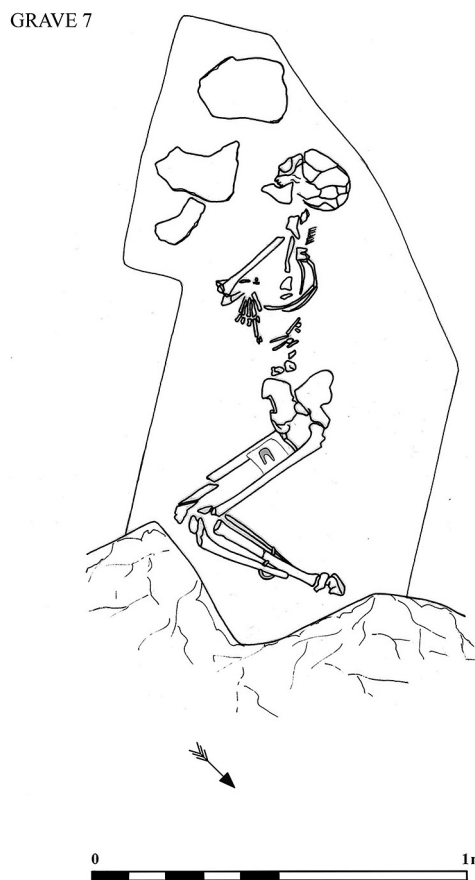


Fig. 2. Skeleton of the adult male, in flexed position, recovered from grave 7 in the Zadar-Relja necropolis

can be dated between the 7th and the 5th centuries BC (Glušćević 2005).

Another inhumation grave excavated during 2009 at the Relja site was almost identical to grave 7 in the manner of its burial. This individual was also interred in plain ground in a flexed position, but with no material artifacts (Alihodžić 2009).

Although these two graves are only approximately 100 metres apart, they are difficult to date more precisely because of the lack of grave architecture and mate-

rial artifacts. The only indicator of grave date is the bronze wire ankle bracelet on grave 7 skeleton. This bronze wire has interwoven endings resembling typical closed-type bracelets worn between the 1st and 4th centuries AD.

While the precise dating of these two graves remains undetermined, their location in the Roman period necropolis, the complete absence of grave architecture and the flexed positions of the skeletons all suggest that these burials occurred in the same chronological period. As already mentioned, the bronze ankle bracelet from grave 7 places this burial between the 1st and 4th century AD, during Roman rule in Zadar. It is therefore most likely that both grave 7 and the second-mentioned grave contained remains of Liburnians who lived during Roman domination, and who preserved Liburnian heritage and ancient Liburnian funeral customs.

Methods used in the analysis

A comprehensive anthropological analysis of skeletal and dental remains of the individual buried in grave 7 in the Zadar-Relja necropolis was conducted in the osteological laboratory of the Anthropological Centre of the Croatian Academy of Sciences and Arts in Zagreb. The gender and the age-at-death of the analyzed individual were determined using methods described in Buikstra and Ubelaker (1994). All observed pathologies were recorded according to criteria proposed by Ortner (2003).

Both external auditory canals were macroscopically examined under powerful illumination of a magnifying glass. The analysis also included recording of exostoses; 1) location (superior, inferior, anterior wall, or posterior wall); 2) size

– small (blocking less than 1/3 of the canal), medium (blocking between 1/3 and 2/3), and large (blocking more than 2/3 and 3) unilateral or bilateral defect (Standen et al. 1997).

Results

The skeleton interred in grave 7 is that of an adult male aged between 35 and 45 years. The skeleton is moderately well preserved, with only several ribs and some of the small bones from the hands and feet missing. Irregularly shaped auditory exostoses are present in both auditory canals, with a somewhat higher degree of expression on the right side (Fig. 3). Exostoses on the left side occur postero-inferiorly and on the anterior wall, while on the right they are mainly present on the superior and posterior walls. They are medium in size on the left side (blocking between 1/3 and 2/3 of the auditory canal) and large on the right (blocking more than 2/3) (Fig. 4).

Pathological changes unrelated to auditory exostoses were observed in this individual. The entire appendicular skeleton is remarkably robust. This is particularly accentuated in the pectoral girdle region and the upper extremities. Benign cortical defects are obvious at the insertion of the *pectoralis major* muscles on both humeri and at attachment sites for the costo-clavicular ligaments on the inferior sternal surfaces of both clavicles (Fig. 5). Osteoarthritis, in the form of slight osteophytes, is present on cervical (C6 and C7) and thoracic vertebral bodies (T6, T7, T8, T9, and T10).

Discussion and conclusion

Most experts today agree that auditory exostosis occurrence is correlated with envi-

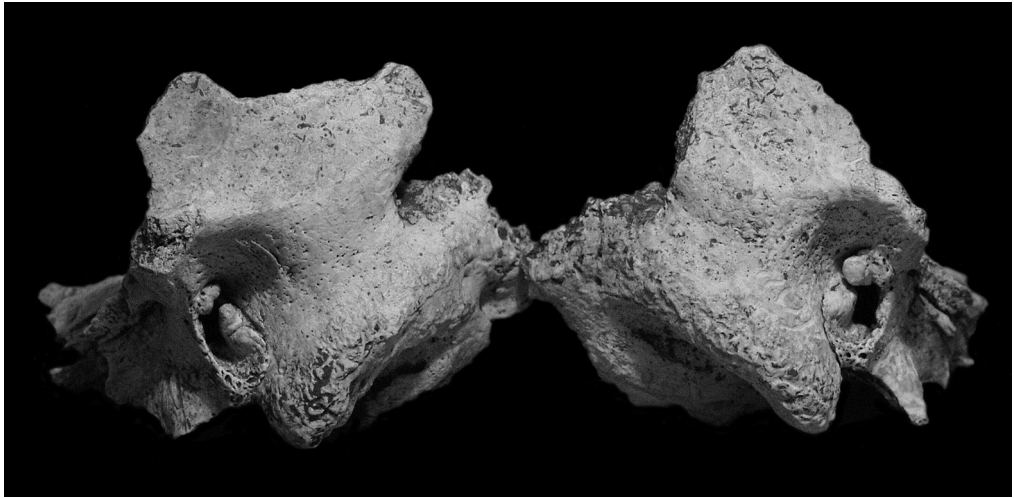


Fig. 3. The left and right temporal bones of the same individual, exhibiting bilateral auditory exostoses

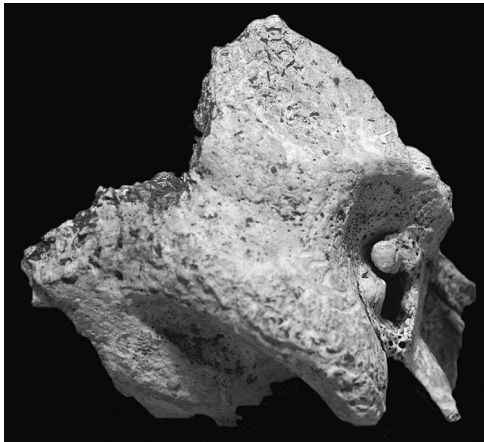


Fig. 4. The right temporal bone with auditory exostosis which occludes more than 2/3 of the auditory canal

most likely associated with activities involving prolonged exposure to cold water. Since these activities include a wide variety of occupations such as shell diving (Kennedy 1986; Standen et al. 1997; Okumura et al. 2007), fishing (Kennedy 1986; Frayer 1988; Standen et al. 1997; Okumura et al. 2007), sailing (Agelarakis and Serpanos 2010), shipbuilding and

boat repairing (Agelarakis and Serpanos 2010; Miladinović-Radmilović 2010), draining marshes and making canals (Miladinović-Radmilović 2010), as well as activities including the frequent use of cold water baths in the *frigidarium* (Manzi et al. 1991) or swimming in order to train (Ascenzi and Balistreri 1975) questions that can to be answered are: “Can we reconstruct these activities in greater detail and thus more precisely? Is it possible to determine the exact occupation this individual performed during his lifetime with the help of historic written records, material artifacts and other pathological changes recorded in the analyzed skeleton?”

To accomplish this it is important to put Zadar as an archaeological site into its specific historical and geographical-climatic context. As already mentioned, Zadar is situated on the eastern Adriatic coast, at north 44° latitude. It has a Mediterranean climate, with very mild, humid winters and very warm, dry summers. The most frequent types of winds occurring in the Zadar region are *bura* (a northerly cold wind which

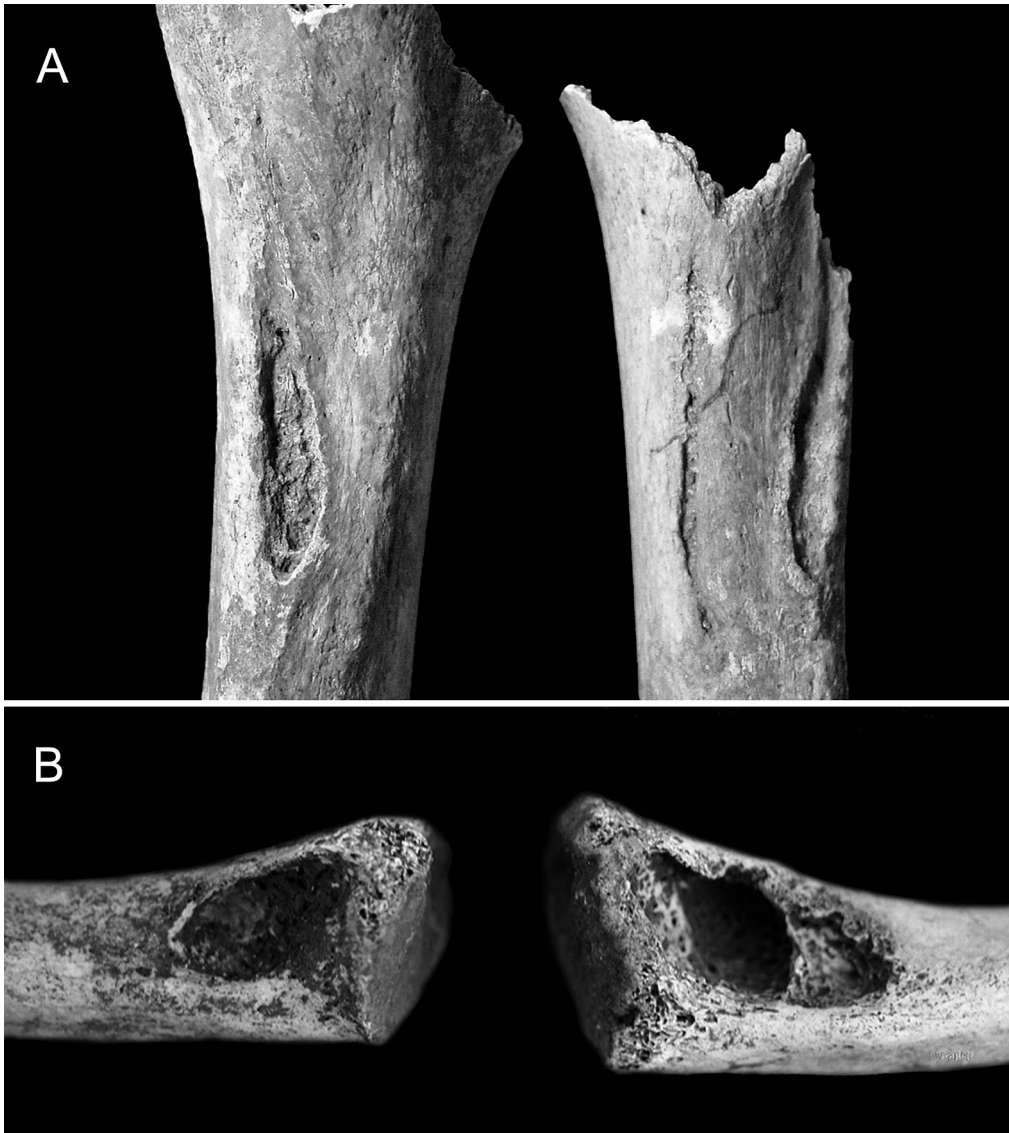


Fig. 5. Pronounced musculoskeletal stress markers on the skeleton buried in grave 7: A) at the insertions of the pectoralis major muscles on both humeri; B) at the attachment sites of the costo-clavicular ligaments on both clavicles

brings good clear weather) and southerly winds (bringing cloudy, rainy but warm weather). These prevail during winter, while *mistral* (a western wind) is more pronounced during summer. However,

in examination of the occurrence of auditory exostoses, the most important climatic characteristic of Zadar is the average sea temperature. The annual average sea temperature in Zadar is 16.2°C,

with lowest average temperatures in February (10.8°C), January (10.9°C), and March (11.3°C). The average sea temperatures exceed 19°C only during the summer months, in June (20.4°C), July (22.3°C), August (22.7°C), and September (21.0°C) (Kraljev et al. 1995).

As a prehistoric settlement, Zadar was founded by the Liburnians in the 9th century BC as one of their major centres. It was a seaport with a safe harbor and the departure point for numerous shipping trade routes (Suić 1981). Following the Roman conquest of the eastern Adriatic coast, Zadar was populated by veteran soldiers and it earned the status of a Roman colony in 48 BC (*Colonia Iulia Iader*). This status was most likely bestowed by Caesar himself (Suić 2003). Zadar's natural, suitably positioned harbour offered safe shelter for ships sailing along the eastern Adriatic coast (Suić 1981).

A large emporium of warehouses for trans-shipment and storage of goods was situated beside Zadar harbour. The recovered imported items clearly attest to the fact that *Iader* maintained intensive trade routes with emporiums in northern Italy (*Aquileia*), and to a lesser extent with the western (*Gallia*) and eastern provinces (Suić 1981). Underwater findings of four Liburnian ships, known as *serillia liburnica*, in Zaton near Zadar and in Caska on the island of Pag, dated to the 1st century AD (Domjan and Brusić 1985; Gluščević 1987, 2002; Brusić 1995; Radić Rossi and Boetto 2011) additionally confirm the importance of Zadar and its region in maritime trade during the late Iron Age and Roman periods as do other discovered shipwrecks of merchant ships from the Roman period in the greater Zadar aquatorium (e.g. Jurišić 2000).

Numerous historical sources testify to the importance of ships and seafaring in

this region during the late Iron Age and early Antiquity. Liburnians were famous skilled sea-traders and pirates. Their ships operated along the entire Adriatic Sea, and according to Strabo (*Geographica*, 6, 269) they even held the island of *Korkyra* - Korfu in modern Greece – during the 8th century BC. The Greek historian Diodorus Siculus (80–29 BC) and a stone Greek inscription recovered from the island of Hvar (dated to 384–383 BC) testify to a great naval battle in the vicinity of Hvar in 384 BC between Greek colonists from Pharos (Hvar) and the *Iadasinoi* (Liburnian inhabitants of Zadar) where over 5,000 *Iadasinoi* lost their lives. This is the first historically documented naval battle in the Adriatic (Novak 1950). Although defeated, the Liburnians recovered and, as recorded by Livius (*Ab Urbe condita*, 10, 2, 4), they continued harassing the navigable routes in the Adriatic (Zaninović, 1988). In 229 BC, the Romans intervened to protect their interests, and Florus (*Epitome*, 1, 21) noted that Liburnians, spread all along the coasts of the Adriatic sea from time immemorial, were the Romans' enemies on this occasion (II, 5).

Appian (*Bell. Civ.*, 2, 39) made a particular note of the *liburnae*, swift galleys that the Romans fought against when they entered the Adriatic, but subsequently, the Liburnians from Zadar provided Caesar with ships during his war against Pompey (*Bell. Alex.*, 1, 42). Liburnian ships are also mentioned by Caesar (*Bell. Civ.*, 3, 9, 1), and as *liburnica navis* they are mentioned by Tacitus (*Hist.*, 2, 16, 35; 3, 12, 77) and Suetonius (*Aug.*, 17).

When all this data is combined with the climatic settings, the presence of pathological changes such as auditory exostoses is not surprising. Unfortunately, archaeological artifacts and burial cus-

toms recorded from grave 7 imply only that the analyzed individual's ethnicity was most likely a Romanized Liburnian, and the approximate time of his death was between the 1st and 4th centuries AD, but they do not reveal anything about his profession. However, other pathological changes exist which help us reconstruct his occupation.

The most telling pathological changes observed in the male from grave 7, apart from the auditory exostoses, are the benign cortical defects at the insertions of the *pectoralis major* muscles on both humeri and at the attachment sites of the costo-clavicular ligaments of both medial clavicles. Benign cortical defects act as musculoskeletal stress markers indicating that they are caused by chronic mechanical stress. In essence, they are linear depressions located at the muscle insertion sites of various skeletal elements, especially the long bones (Owsley et al. 1991), and as such are reliable indicators of heavy physical labour. The *pectoralis major* muscle inserts on the lateral lip of the intertubercular groove of the humerus and functions in adducting and medially rotating the arm, flexing and extending the humerus, and its fixed insertion point assists in elevating the thorax (Cunningham 1905). The costo-clavicular ligament attaches on the costal impression of the clavicle. It limits elevation of the pectoral girdle and acts as a fulcrum during clavicular elevation, (Cave 1961). The etiology of cortical defects at the attachment sites of the costo-clavicular ligaments on clavicles, also referred to as "kayaker's clavicle" (Hawkey and Merbs 1995: 333), can be associated with strenuous activity of the pectoral girdle (Mann and Murphy 1990).

Severe skeletal changes involving the pectoral girdle and upper limbs, especial-

ly *pectoralis major* muscles and costo-clavicular ligaments, have been observed in other archaeological skeletal collections. In these studies, the recorded changes were associated with activities involving watercraft propulsion; as in long-term and intensive use of paddles and/or oars (Hawkey and Street 1992; Lai and Lowell 1992; Hawkey and Merbs 1995; Eshed et al. 2004; Lieverse et al. 2009; Agelarakis and Serpanos 2010). In their study of musculoskeletal stress indicators in ancient Hudson Bay Eskimos, Hawkey and Merbs (1995) suggested that intensive male use of kayaks with double-bladed paddles caused heavy bilateral stress at the attachment site of the costo-clavicular ligament, and also on *teres major* and *pectoralis major* muscle attachments. Eshed et al. (2004: 314) concluded that combined use of the costoclavicular ligament and *pectoralis major* muscle is consistent with movements "requiring an alternating rotary motion of the shoulder girdle, a movement that has been interpreted as the likely result of using a double-bladed paddle in a boat".

Although osteoarthritic changes recorded on the cervical and thoracic vertebral bodies in this Zadar male may be connected with age, they correlate extremely well with chronic mechanical stress and damage related to occupation. Numerous studies of archaeological series (Rogers et al. 1987; Knüsel et al. 1997; van der Merwe et al. 2006; Novak and Šlaus 2011) and modern clinical research (Spector and MacGregor 2004), stress that age, repetitive mechanical loading, movement, and genetic influences are the main causes of the presence and severity of vertebral osteoarthritis. Without delving further into the formation of vertebral osteoarthritis, it is possible to surmise that the arthritic chang-

es recorded in this individual are related to his continuous, long-term, hard physical labour in seafaring connected activities. A similar suggestion was proposed by Stirland and Waldron (1997) in their comprehensive study of vertebral pathologies recorded in the skeletal remains of the crew of the ship *Mary Rose*. Here, they concluded that the pathological changes of Schmorl's nodes and vertebral osteoarthritis in the spines of the members of the *Mary Rose* crew were almost identical to those in an older group of men from the medieval parish cemetery in Norwich, and that these changes were related to activities performed on board ship.

One of the most comprehensive studies of auditory exostoses and reconstructions of possible habitual activities based on musculoskeletal stress markers was conducted by Agelarakis and Serpanos (2010). They recorded bilateral auditory exostoses in an adult male from the Greek town of Thasos dated between the 5th and 3rd centuries BC. Combining archaeological evidence, historic records, anthropological data, and ethnographic documentation, they concluded that the individual in their study, who also exhibited auditory exostoses, was most likely a crew member responsible for repairing moored or hauled wooden boats, and that the specific role of this individual was to dive and investigate the vessel's submerged hull (Agelarakis and Serpanos 2010).

Following careful evaluation of all data presented in this paper, we consider that the most plausible profession of the individual whose remains were recovered from grave 7 in the Zadar-Relja cemetery was closely associated with prolonged exposure to cold water – resulting in development of large bilateral exostoses in the external auditory canal. This deter-

mination is strengthened by the fact that Zadar is situated at 44° north latitude and that the average annual sea temperature there is 16.2°C. This is fully consistent with Kennedy's (1986) hypothesis that most auditory exostoses in past societies occurred in populations living between the 30° and 45° north and/or south latitudes where water temperatures are usually below 19°C. It is possible that the auditory exostoses in this individual resulted from activities related to the frequent use of cold water baths in the *frigidarium* (Manzi et al. 1991), or from shell diving (e.g. Okumura et al. 2007), but the simultaneous presence of identified pathological changes indicating constant heavy physical labour render these pastimes highly unlikely. The changes include pronounced skeletal robustness and musculoskeletal stress markers on the pectoral girdle and upper limbs in combination with cervical and thoracic vertebral body arthritis. These changes are entirely consistent with chronic mechanical stress suffered undertaking vigorous activities aboard a sea vessel. Our hypothesis is further confirmed by numerous historical sources which attest to the exceptional role that seamanship and ships played in the everyday life of the late Iron Age and early Roman inhabitants of Iader and its surrounds. In summary, the observed physical characteristics of the studied skeleton, combined with historic documents and material artifacts, strongly suggest that the individual interred in grave 7 in the Zadar-Relja necropolis was most likely a Romanized Liburnian who spent most of his life working aboard a sea vessel as a sailor, boat builder or fisherman, and whose duties, among others, included frequent and intensive use of oars. Although we are currently unable to elucidate further

details of this individual's life, the results of future multidisciplinary studies, especially the ongoing archaeological excavations at the site and planned stable isotope analysis, should more precisely define his life-style and profession.

Acknowledgments

The authors thank Dr. Smiljan Gluščević, director of the Archaeological Museum Zadar, and also the two anonymous reviewers for their constructive suggestions and comments. This study was financially supported by Grant No. 101-197-0677-0670 from the Ministry of Science, Education and Sports of the Republic of Croatia.

Author contribution

MN anthropological analysis, figures and main part of the manuscript; TA excavation, archaeological context, historical data and proofreading; MŠ anthropological analysis, comparison with similar cases, conclusions and proofreading.

Conflict of interests

The authors declare that there is no conflict of interests

Corresponding author

Dr. Mario Novak, Anthropological Centre, Croatian Academy of Sciences and Arts, Ante Kovačića 5, 10 000 Zagreb, Croatia
e-mail address: mnovak@hazu.hr

References

- Agelarakis PA, Serpanos Y. 2010. Auditory Exostoses, Infracranial Skeleto-Muscular Changes and Maritime Activities in Classical Period Thasos Island. *Mediterranean Archaeology and Archaeometry* 10:45–57.
- Alihodžić T. 2009. Relja – parkiralište. *Hrvatski arheološki godišnjak* 6:540–43.
- Ascenzi A, Balistreri P. 1975. Aural exostoses in a Roman skull excavated at the “Baths of the swimmer” in the ancient town of Ostia. *J Hum Evol* 4:579–84.
- Aufderheide AC, Rodríguez-Martín C, Langsjoen O. 1998. *The Cambridge Encyclopaedia of Human Paleopathology*. Cambridge: University Press.
- Berry AC. 1975. Factors affecting the incidence of non-metrical skeletal variants. *J Anat* 120:519–35.
- Blake C. 1880. The occurrence of exostoses within the external canal in prehistoric man. *Am J Otol* 2:81–91.
- Brusić Z, Domjan M. 1985. Liburnian boats – their construction and form. In S McGrail, E Kentley, editors. *Sewn Plank Boats*. BAR International Series 276. Oxford: Archaeopress. 67–85.
- Brusić Z. 1995. *Serillia liburnica*. *Radovi Zavoda za povijesne znanosti HAZU u Zadru* 37:39–59.
- Buikstra JE, Ubelaker DH. 1994. *Standards for data collection from human skeletal remains*. Fayetteville: Arkansas Archaeological Survey.
- Cave AJE. 1961. The nature and morphology of the costoclavicular ligament. *J Anat* 95:170–79.
- Chaplin JM, Stewart IA. 1998. The prevalence of exostoses in the external auditory meatus of surfers. *Clin Otolaryngol* 23:326–30.
- Cunningham DJ. 1905. *Textbook of Anatomy*. New York: W. Wood & Company.
- DiBartolomeo JR. 1979. Exostoses of the external auditory canal. *Ann Otol Rhinol Laryngol* 88:2–20.
- Eshed V, Gopher A, Galili E, Hershkovitz I. 2004. Musculoskeletal stress markers in Natufian hunter-gatherers and Neolithic farmers in the Levant: the upper limb. *Am Journal Phys Anthropol* 123:303–15.

- Fabiani M, Barbara M, Filipo R. 1984. External ear canal exostosis and aquatic sports. *ORL J Otorhinolaryngol Relat Spec* 46:159–64.
- Filipo R, Fabiani M, Barbara M. 1982. External ear canal exostosis: A physiopathological lesion in aquatic sports. *J Sports Med Phys Fitness* 22:329–39.
- Frayser DW. 1988. Auditory exostoses and evidence for fishing at Vlasac. *Current Anthropology* 29:346–49.
- Gerszten PC, Gerszten E, Allison MJ. 1998. Diseases of the skull in pre-Columbian South American mummies. *Neurosurgery* 42:1145–51.
- Glušćević S. 1987. Vađenje antičkog broda iz Zatonu. *Obavijesti Hrvatskog arheološkog društva* 3/1987:33–43.
- Glušćević S. 2002. Hidroarheološko istraživanje i nalaz trećeg liburnskog broda u antičkoj luci u Zatonu kod Zadra. *Obavijesti Hrvatskog arheološkog društva* 3/2002:76–86.
- Glušćević S. 2005. Zadarske nekropole od 1. do 4. st. Unpublished PhD dissertation. Zadar: Sveučilište u Zadru.
- Hawkey DE, Street SR. 1992. Activity-induced stress markers in prehistoric remains from the eastern Aleutian Islands. *Am J Phys Anthropol* 14:89.
- Hawkey DE, Merbs CF. 1995. Activity-induced musculoskeletal stress markers (MSM) and subsistence strategy changes among ancient Hudson Bay Eskimo. *Int J Osteoarchaeol* 5:324–38.
- Hrdlicka A. 1935. Ear exostoses. *Am J Phys Anthropol* 20:489–90.
- Jurišić M. 2000. Ancient Shipwrecks of the Adriatic. Maritime transport during the first and second centuries AD. *BAR International Series* 828. Oxford: Archaeopress.
- Kennedy GF. 1986. The relationship between auditory exostoses and cold water: a latitudinal analysis. *Am J Phys Anthropol* 71:401–15.
- Knüsel CJ, Gögel S, Lucy D. 1997. Comparative degenerative joint disease of the vertebral column in the medieval monastic cemetery of the Gilbertine Priory of St. Andrew, Fishergate, York, England. *Am J Phys Anthropol* 103:481–95.
- Kraljev D, Gajić-Čapka M, Zaninović K. 1995. U okrilju sunca i mora: klimatska monografija Zadra. Zadar: Hrvatsko meteorološko društvo.
- Kroon DE, Lawson ML, Derkey CS, Hoffman K, McCook J. 2002. Surfer's ear: external auditory exostoses are more prevalent in cold water surfers. *Otolaryngol Head Neck Surg* 126:499–504.
- Lai P, Lowell NC. 1992. Skeletal Markers of Occupational Stress in the Fur Trade: a Case Study from a Hudson's Bay Company Fur Trade Post. *Int J Osteoarchaeol* 2:221–34.
- Lieverse AR, Bazaliiskii VI, Goriunova OI, Weber AW. 2009. Upper limb musculoskeletal stress markers among middle Holocene foragers of Siberia's Cis-Baikal region. *Am J Phys Anthropol* 138:458–72.
- Mann WR, Murphy PS. 1990. Regional atlas of bone disease. Springfield: C.C. Thomas:.
- Manzi G, Sperduti A, Passarello P. 1991. Behavior-induced auditory exostoses in Imperial Roman society: evidence from coeval urban and rural communities near Rome. *Am J Phys Anthropol* 85:253–60.
- Miladinović-Radmilović N. 2010. Exostoses of the external auditory canal. *Starinar* 60:137–46.
- Novak G. 1962. Jadransko more u borbama i sukobima kroz stoljeća. Beograd: Vojnoizdavački zavod JNA Vojno delo.
- Okumura MMM, Boyadjian CHC, Eggers S. 2007. Auditory Exostoses as an Aquatic Activity Marker: A Comparison of Coastal and Inland Skeletal Remains from Tropic and Subtropical Regions of Brazil. *Am J Phys Anthropol* 132:558–67.
- Novak M, Šlaus M. 2011. Vertebral pathologies in two early modern period (16th–19th century) populations from Croatia. *Am J Phys Anthropol* 145:270–81.
- Ortner DJ. 2003. Identification of Pathological Conditions in Human Skeletal Remains. San Diego: Academic Press.

- Owsley DW, Mann RW, Murphy SP. 1991. Injuries, surgical care and disease. In S Pfeiffer, RF Williamson, editors. *Snake Hill: an Investigation of a Military Cemetery from the War of 1812*. Toronto: Dundurn Press. 198–226.
- Radić Rossi I, Boetto G. 2011. Šivani brod u uvali Caska na Pagu – istraživačka kampanja 2010. *Histria Antiqua* 20:505–13.
- Rogers J, Waldron T, Dieppe P, Watt I. 1987. Arthropathies in palaeopathology: The basis of classification according to most probable cause. *Journal of Archaeological Science* 14:179–93.
- Sakalinskas V, Jankauskas R. 1993. Clinical otosclerosis and auditory exostoses in ancient Europeans (investigation of Lithuanian paleoosteological samples). *J Laryngol Otol* 107:489–91.
- Spector TD, MacGregor AJ. 2004. Risk factors for osteoarthritis: genetics. *Osteoarthritis Cartilage* 12(S):39–44.
- Standen VG, Arriaza BT, Santoro CM. 1997. External auditory exostosis in prehistoric Chilean populations: A test of the cold water hypothesis. *Am J Phys Anthropol* 103:119–29.
- Stirland AJ, Waldron T. 1997. Evidence for activity related markers in the vertebrae of the crew of the Mary Rose. *Journal of Archaeological Science* 24:329–35.
- Suić M. 1981. Zadar u starom vijeku. Zadar: Filozofski fakultet.
- Suić M. 2003. Antički grad na istočnom Jadranu. Zagreb: Golden marketing.
- van der Merwe AE, Işcan MY, L'Abbè EN. 2006. The pattern of vertebral osteophyte development in a South African population. *Int J Osteoarchaeol* 16:459–64.
- Velasco-Vazquez J, Betancor-Rodriguez A, Arnay-de-la-Rosa M, Gonzalez-Reimers E. 2000. Auricular exostoses in the Prehistoric Population of Gran Canaria. *Am J Phys Anthropol* 112:49–55.
- Zaninović M. 1988. *Liburnia Militaris*. *Opuscula Archeologica* 13:43–67.