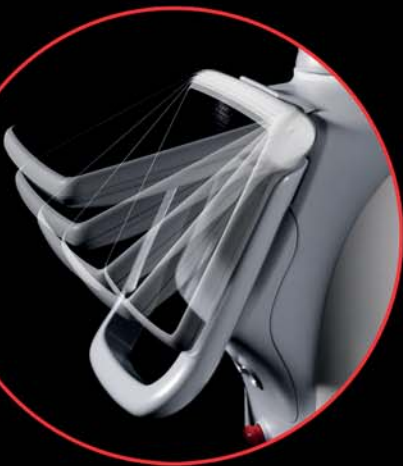
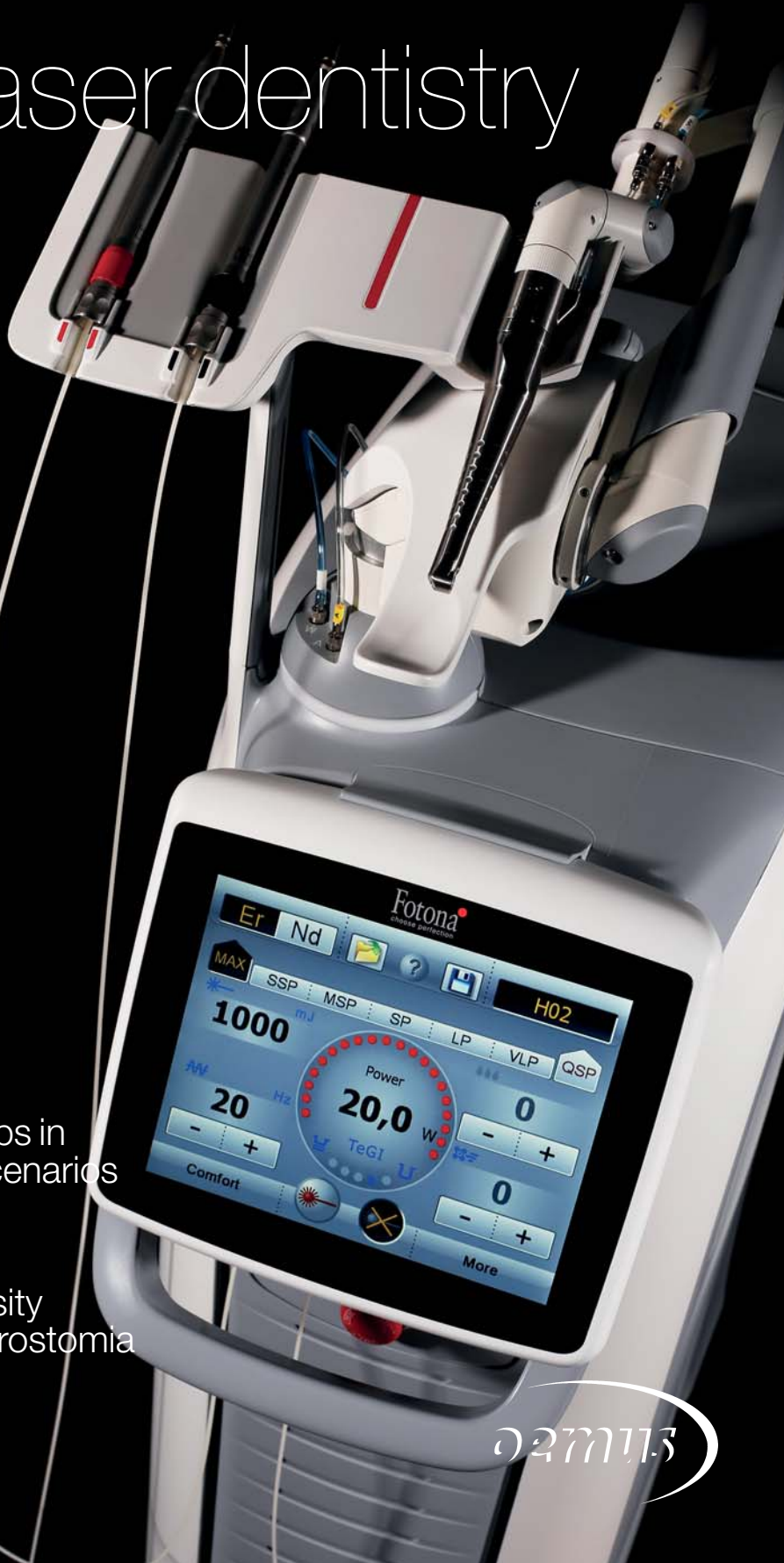

# laser

international magazine of laser dentistry

4<sup>2013</sup>



| **research**

Er,Cr:YSGG laser and radial firing tips in highly compromised endodontic scenarios

| **case report**

The efficacy of combined low intensity laser therapy and medication on xerostomia

| **industry report**

Lasers in aesthetic dentistry



# BE AMAZED BY WATERLASE®

The WaterLase iPlus system is simply amazing. It is our most advanced, most powerful and simplest WaterLase yet. But don't take our word for it. See for yourself at

[AMAZEDBYWATERLASE.COM!](http://AMAZEDBYWATERLASE.COM!)

**+ BREAKS THE SPEED BARRIER**

- Up to 100/pulses per second
- Patented tech delivers 600 mJ/pulse
- As fast as a high-speed drill

**+ ILASE 940nm DIODE LASER DOCKING STATION**

- Adds dual wavelength convenience
- First totally wireless diode laser
- Battery operated with finger operation

**+ INTUITIVE USER INTERFACE**

- 52 illustrated procedure pre-sets
- Touch-screen controls
- Greatly simplifies the learning curve

**+ BIOLOGICALLY FRIENDLY DENTISTRY**

- No micro-fractures or thermal damage
- More precise, minimally invasive
- Relies on water and light to cut

**CONTACT US TO LEARN MORE  
ABOUT WATERLASE IPLUS!**

OR VISIT [AMAZEDBYWATERLASE.COM](http://AMAZEDBYWATERLASE.COM) TO VIEW  
INSTANT REACTIONS FROM DOCTORS AND PATIENTS!

**GO TO [BIOLASE.COM](http://BIOLASE.COM) TO FIND  
YOUR LOCAL DISTRIBUTOR.**



**THE ONLY LASER FOR:  
SOFT TISSUE • WHITENING • PAIN THERAPY**

©BIOLASE, Inc. All rights reserved. For use by licensed professionals only. BIOLASE, WaterLase, iPlus, and Deep Pocket Therapy with New Attachment are trademarks of BIOLASE, registered in the U.S. and other countries.

FOLLOW US!

[f](#) [t](#) [in](#) [yt](#) [p](#) [g](#) | [www.biolase.com](http://www.biolase.com) | +1.949.361.1200

**BIOLASE®**

# DGL and its role in evidence-based dentistry



Prof. Dr. Norbert Gutknecht  
Editor-in-Chief

Dear colleagues,

In order to fulfill its claim to be a scientific-oriented, science-based dental society, the German Society for Laser Dentistry has chosen the motto "Evidence-based Dentistry" for this year's annual congress. It is undisputable that laser application has not met the qualitative demands of evidence-based dentistry for many years. Instead, laser dentistry has developed from therapeutically useful and successful applications. In spite of this, already since it was founded, DGL has always aimed at supporting scientific-based laser applications in dentistry. This objective, the associated efforts and gradual successes have finally led to DGL being fully integrated within the German Society of Dental, Oral and Craniomandibular Sciences (DGZMK) which is the scientific umbrella organization of all dental societies.

DGZMK can thus be trend-setting for all societies of laser dentistry which want to gain support and recognition by the established dental societies of their countries.

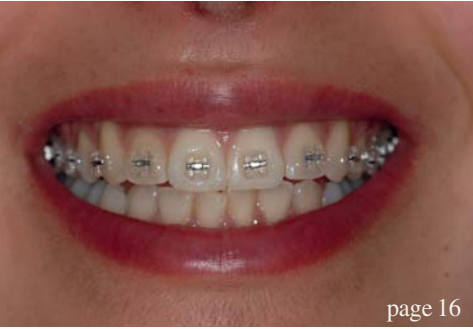Last year, DGL supported in an exemplary way the scientific work of colleagues who have been busy revising investigations in evidence-based dentistry which were conducted in 2006. Therefore, this year's congress features scientifically established national and international speakers, who will provide both DGL members and visitors of the congress with the state-of-the-art of evidence-based laser applications in dentistry.

With this in mind, I wish the German Society for Laser Dentistry all the best for their upcoming annual congress.

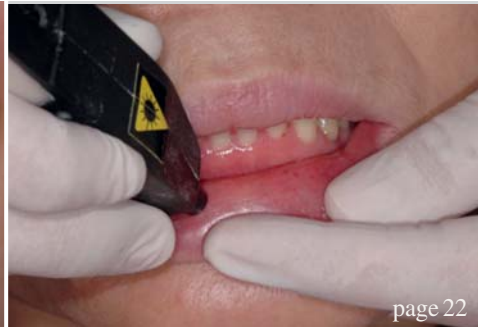Kind regards,

A handwritten signature in black ink, appearing to read 'N. Gutknecht', written in a cursive style.

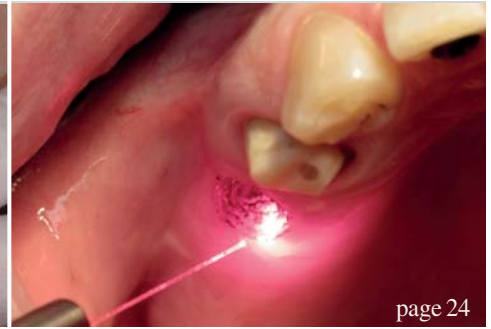Prof. Dr. Norbert Gutknecht



page 16



page 22



page 24

| editorial

03 **DGL** and its role in **evidence-based dentistry**  
| Prof. Dr Norbert Gutknecht

| research

06 **Laser therapy** in dentistry  
| Dr Kirpa Johar

10 **Er,Cr:YSGG laser** and **radial firing tips** in highly **compromised endodontic** scenarios  
| Miguel Rodrigues Martins **et al.**

16 **Er:YAG laser** in the **bonding** and **debonding** steps of **orthodontic** treatment  
| Prof. Carlo Fornaini

| case report

22 The **efficacy** of combined **low intensity laser therapy** and **medication** on **xerostomia**  
| Dr Sawanya Taboran **et al.**

| industry report

24 A **combined** device for optimal **soft tissue** applications in **laser** dentistry  
| Hans J. Koort **et al.**

30 **Lasers** in aesthetic dentistry  
| Dr Ilay Maden **et al.**

| economy

34 **Gain power** at your **laser** clinics!  
| Dr Anna Maria Yannikos

| health

36 **The right to be** pain free  
| Dr Michael Sultan

| interview

40 **Biolase** could become the **next Intuitive Surgical**

42 **Dentures produced using 3-D** printing versus casting and milling

| meetings

46 **Jean-Paul Rocca** new **President of IPTA**  
| Prof. Carlo Fornaini

47 **International** events 2013 & 2014

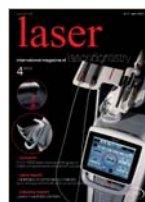| news

38 **Manufacturer** News


48 **News**

| about the publisher


50 | imprint




Cover image courtesy of Fotona, [www.fotona.com](http://www.fotona.com)



page 36

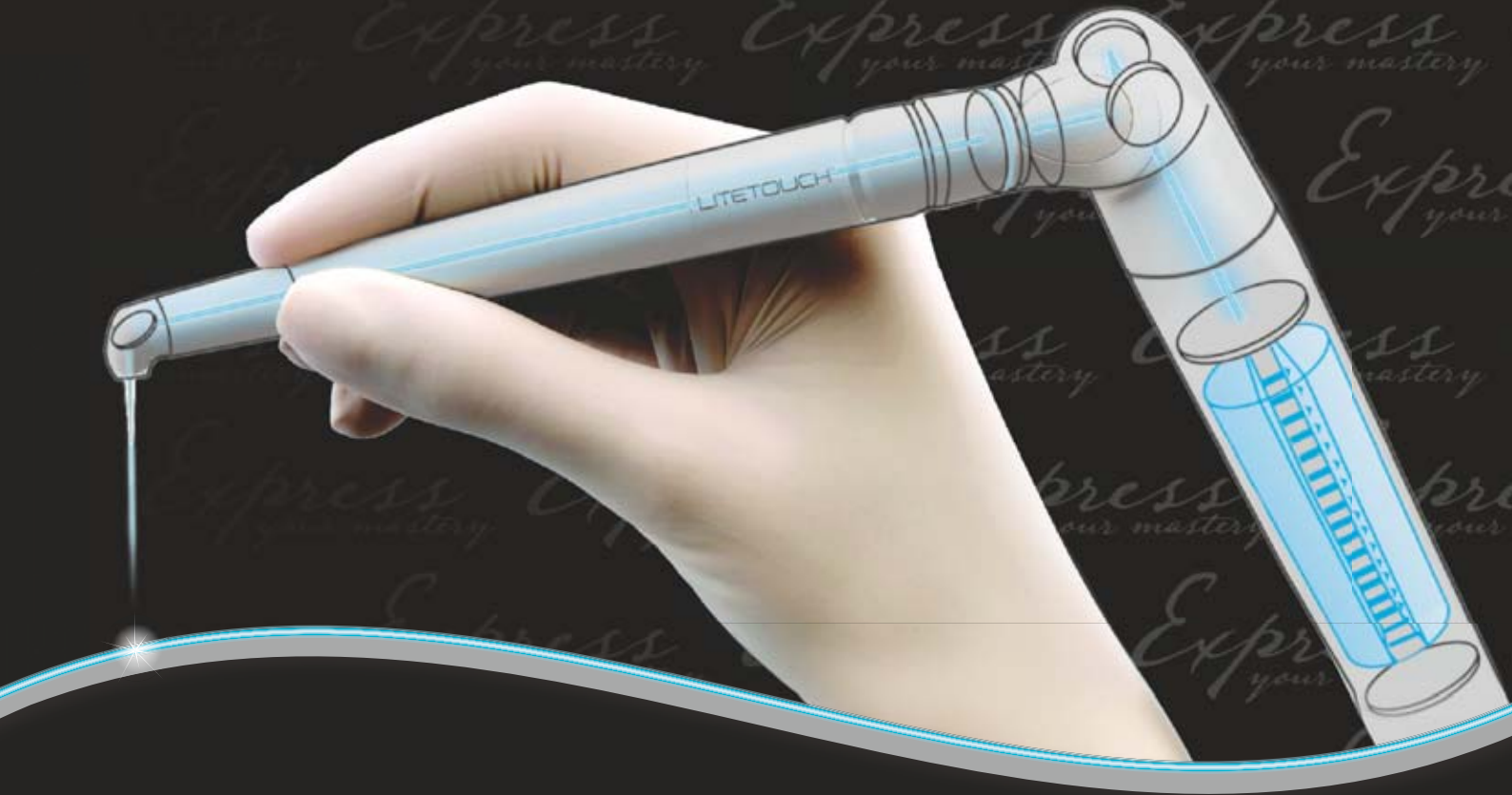

page 40



page 46

**Syneron™**  
DENTAL LASERS



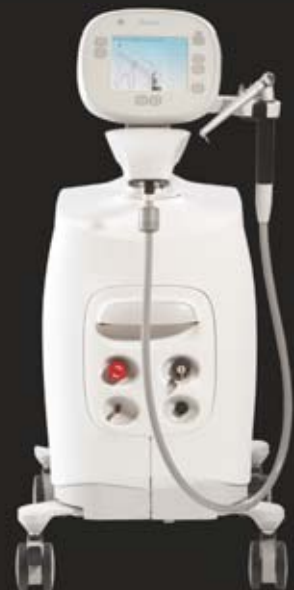Education. Technology. Family.

Join the Syneron Dental Lasers Family

presenting

**LITETOUGH™**

The unique fiber-free Er:YAG laser  
that has changed the face of laser dentistry



L-197/7692EN



To learn more about our innovative technology solutions,  
contact: [dental@syneron.com](mailto:dental@syneron.com), [www.synerondental.com](http://www.synerondental.com)



# Laser therapy in dentistry

Author\_Dr Kirpa Jonar, India

[PICTURE: ©PIXEL EMBARGO]

## \_Introduction

The Therapeutic laser is a new tool which can be a boon to the dental practice. Laser Therapy is also known as Photo-Biomodulation. It is based on the concept that certain low level doses of specific coherent wavelengths can turn on or turn off certain cellular components or functions. Administering laser therapy to patients helps in healing, reducing pain, swelling and controlling oral infections.

The wavelengths used for Laser Therapy have poor absorption in water and thus penetrate soft and hard tissues from 3 mm up to 15 mm. Therapeutic lasers generally operate in the visible and the infrared spectrum, 600–900 nm wavelength. The energy used is indicated in Joule (J), which is the number of milliwatts

x the number of seconds of irradiation. High power surgical lasers can be defocused and arranged to give energy densities of the same values as the former. Thus, a therapeutic laser could be defined as a laser using energy densities below the threshold where irreversible changes in cells occur.

## \_Mechanism of action

The principle of using laser therapy is to supply direct biostimulative light energy to the body's cells. Cellular photoreceptors can absorb low-level laser light and pass it on to mitochondria, which promptly produce the cell's fuel, ATP. The most beneficial effect of laser therapy is wound healing. Studies have shown the evidence of accumulated collagen fibrils and electron dense vesicles intracytoplasmically within the

**Fig. 1**\_ Bio stimulation headpiece used for Intra-Oral therapy.

**Fig. 2**\_Preoperative (a), laser-assisted biostimulation (b), after three days (c), after one week (d).



Fig. 1

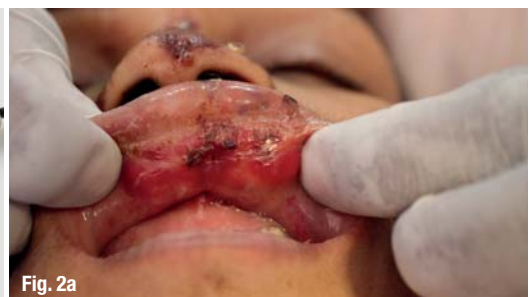

Fig. 2a

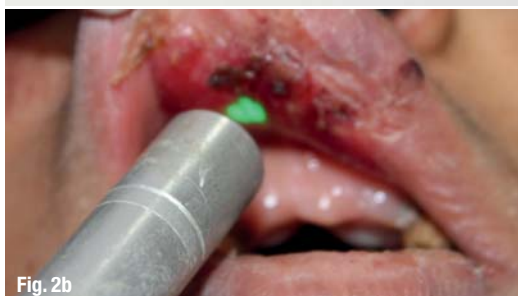

Fig. 2b

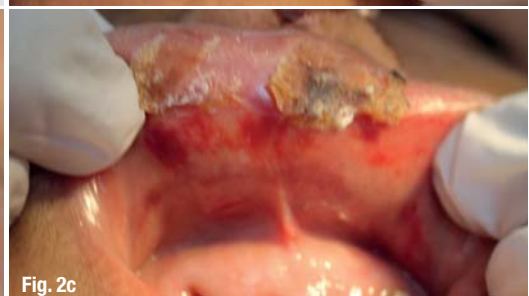

Fig. 2c



# Master of Science (M.Sc.) in Lasers in Dentistry

Batch: EN2014 - Fulltime (new) or Module based

Next Start: **22 September 2014**  
Aachen, Germany  
4 semesters

## Become part of the International Dental Elite

- Create new economic potential for your practice
- Two year career-accompanying postgraduate programme at the University of Excellence RWTH Aachen
- Combination of lectures, skill training sessions, live ops, tutorials, and practical workshops
- Internationally accepted and accredited by the German Government, the European Union, the Washington Accord and the Bologna Process
- Science-based and practice-orientated on highest national and international level
- Increased patient satisfaction: minimal contact reduced vibration and pain



**RWTH INTERNATIONAL ACADEMY**  
**AACHEN UNIVERSITY**

RWTH International Academy  
Kackertstraße 10 | 52072 Aachen | Germany  
phone +49 241 80 23543 | fax +49 241 80 92525  
info@academy.rwth-aachen.de  
www.academy.rwth-aachen.de

**PROFESSIONAL EDUCATION PROGRAMMES**



**Aachen Dental Laser Center**

AALZ GmbH  
Pauwelsstraße 17 | 52074 Aachen | Germany  
phone +49 241 47 57 13 10 | fax +49 241 47 57 13 29  
info@aalz.de  
www.aalz.de

laser stimulated fibroblasts as compared with untreated areas. Increased microcirculation can be observed with the increased redness around the wound area.

The analgesic effects can be understood with some evidence suggesting that laser therapy may have significant neuropharmacologic effects on the synthesis, release and metabolism of a range of neurochemicals, including serotonin and acetylcholine at the central level and histamine and prostaglandin at the peripheral level.

### Common indications for laser therapy in dentistry

#### Alveolitis

Laser phototherapy (LPT) directly after extraction helps to prevent alveolitis. If it is already established, 4–5 J before and after the alveolus is debrided and plugged with medication is recommended. Irradiate the alveolus and its surrounding area directly. If the alveolitis is very painful, then 15–20J can be used.

#### Anaesthetics

Some patients are difficult to anaesthetize. By administering 2–3 J over the apex, circulation is increased and the anaesthetic is more quickly absorbed. This also means that the duration is reduced. The duration of numbness in the lip after anaesthesia can therefore be reduced by LPT. This can be advantageous in paediatrics.

#### Bleeding

A laser is useful in the treatment of postoperative bleeding. Although the mechanism is unclear, literature shows that LPT brings about initial vasoconstriction that is followed by vasodilatation.

#### Pulpal analgesia

In selected patients, using the 660-nm laser probe can achieve adequate pulpal analgesia. Successful analgesia may allow a dentist to use a high speed drill to prepare a class II restoration without the need for any local anaesthesia.

Treatment consists of placing the laser probe on the occlusal surface of a primary molar for one to two minutes. In permanent teeth, placing the probe for one minute next to gingival tissue over the roots of the treated tooth also contributes to successful analgesia.

#### Trauma

Trauma to a primary anterior tooth may compromise the tooth's vitality and result in requiring either a pulpotomy or extraction in a four- to six-week period.

A tooth or teeth which have been significantly displaced may respond positively if treatment is begun within a few hours of trauma. Treatment consists of placing the laser over the injured tooth for a period of one minute on the facial root area and one minute on the lingual or palatal root area. An additional treatment in 24 to 36 hours may improve the chance of successfully healing the tooth.

#### Healing of soft tissue trauma

Patients who fall and receive facial lacerations and swelling benefit from placing the laser/light-emitting diode (LED) unit over the area for approximately three minutes and placing the 660-nm or 808-nm probe over the most injured area for one to two minutes, helping to heal the lesions more quickly and with less post trauma discomfort. Additional treatment 24 to 36 hours later may be needed to reduce the discomfort and improve healing.

**Fig. 3** Laser-assisted haemostasis (a), after first session of laser therapy (b), after one week (c), immediately after extraction (d).

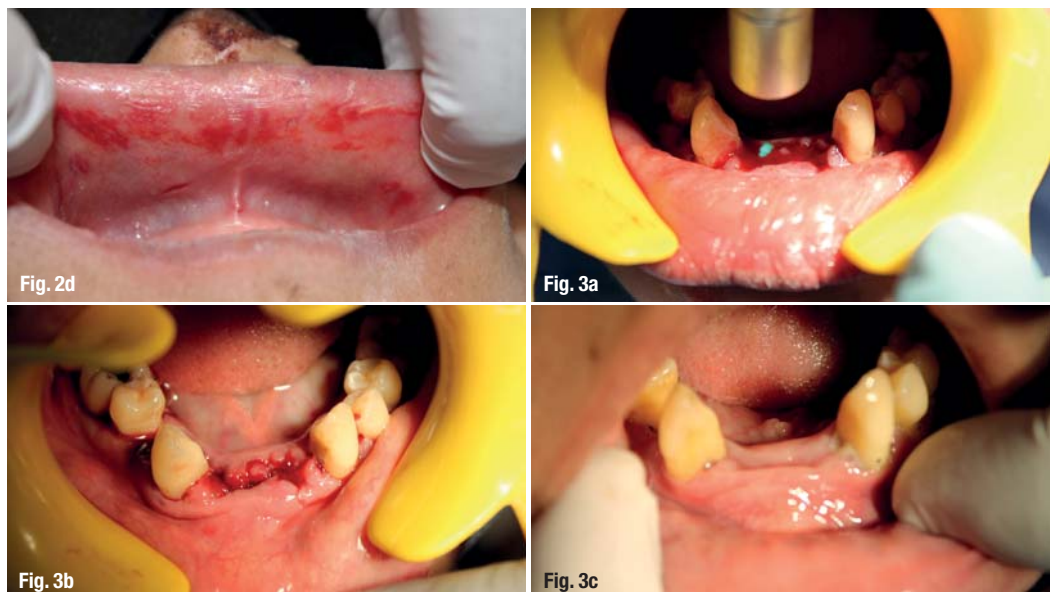



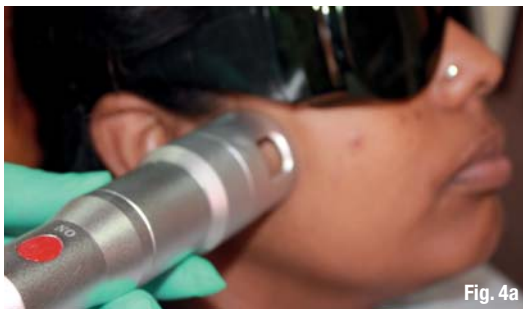


Fig. 4a

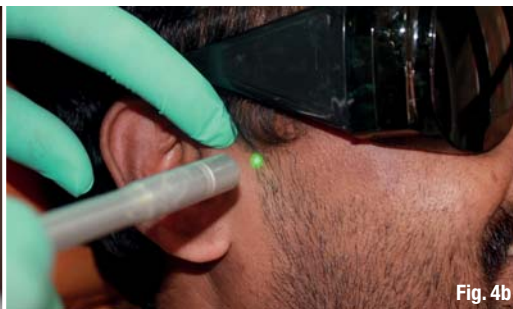

Fig. 4b

**Fig. 4\_**Extraoral biostimulation (TMJ) – with high power laser therapy (a), extraoral biostimulation (TMJ) – with a biostimulation hand piece (b).

*Post extraction and bone healing therapy*

It is useful to irradiate the area before and after an extraction. Irradiating before the extraction with 1 J at the injection site and 2 J right below the apices induces a transient but useful effect. After extraction, an additional 2J/cm<sup>2</sup> on the alveolar and gingival tissues is needed to control the swelling and inflammation. Less postoperative pain and better healing can be expected.

*Aphthous ulcer*

Laser therapy for the treatment of apthae can be recommended for its pain relieving effect and the shortened healing time. The treatment dosage is the same for herpes and apthae; 2J/cm<sup>2</sup> applied near contact. This is repeated the following day.

*Mucositis*

Patients undergoing radiation therapy or chemotherapy develop mucositis. Mucositis is painful and may force the oncologist to reduce the dosage or number of sessions. Red laser light has been shown to reduce the severity of mucositis and can be used prophylactically before radiation.

*Trigeminal neuralgia*

Laser phototherapy has been documented to have a pain relieving effect on trigeminal neuralgia. Studies have shown that patients treated with low level therapy are more likely to be relieved of pain by the end of the first year.

*Tempromandibular joint dysfunction*

Problems in the tempromandibular joint region are quite suitable for laser therapy. For arthritic cases, the treatment is concentrated to the joint area, in myogenic cases the muscular insertions and trigger points are treated. Laser therapy should always be used in combination with conventional treatment but will improve the outcome of the treatment. Tempromandibular joint-pain biostimulation of the TMJ and masseter muscles is effective for pain relief, especially in situations of acute locking.

*Periodontitis*

The use of laser therapy helps to control the symptoms and conditions of periodontitis. The anti-inflam-

matory effect slows or stops the deterioration of periodontal tissues and reduces the swelling to facilitate the hygiene in conjunction with scaling, root planning, curettage or surgical treatment. As a result, there is an accelerated healing and less post operative discomfort.

**Laser therapy in medically compromised patients**

*Pacemaker*

As pacemakers are electronic and cased in metal they are not influenced by light. Hence, low level laser therapy on patients with pacemakers should not be considered a total contraindication.

*Cancer*

Laser phototherapy can provide palliative treatment to cancer patients. LPT is a viable option for pain control and general stimulation in these patients.

*Epilepsy*

Pulsed visible light, particularly at pulse frequencies in the 5–10 Hz range can cause epileptic attacks, one should obviously be careful with instruments that use flashing visible light. However, it is rare for therapeutic lasers to have pulsing visible light.

**Conclusion**

LPT has been found to accelerate wound healing and reduce pain, by stimulating oxidative phosphorylation in mitochondria and modulating inflammatory responses. The enhanced cell metabolic functions seen after laser therapy are the result of activation of photoreceptors within the electron transport chain of mitochondria. Because of the many advantages laser therapy provides, it is gaining momentum as an irreplaceable treatment modality in modern dental practice.

**\_contact**

**laser**

**Dr Kirpa Johar**

Director Laser Dentistry Research And Review

Bangalore, India

www.lldr.org

# Er,Cr:YSGG laser and radial firing tips in highly compromised endodontic scenarios

**Authors** Miguel Rodrigues Martins, Manuel Fontes Carvalho, Irene Pina-Vaz, José Capelas, Miguel André Martins, Portugal & Norbert Gutknecht, Germany

## Introduction

As bacterial contamination is considered the primal etiologic factor for the development of pulpal and periapical lesions, to obtain the root canal system free of irritants has been showing to be the primordial endodontic therapy goal.<sup>1-3</sup>

The idea that an absence of cultivable microbes at the time of obturation will favor healing is consistent with the notion that microorganisms are the primary cause of persistent apical periodontitis.<sup>4</sup> Accordingly, other investigators have suggested that the presence of microbes at the time of root filling will adversely affect the outcomes.<sup>5-7</sup> The bactericidal effects of conventional irrigation strategies during and after root canal preparation with solutions such sodium hypochlorite (NaOCl) have been studied by numerous investigators, the ideal concentration and temperature of NaOCl in root canal therapy remains as controversy and topic of debate within endodontists.<sup>8-11</sup>

In fact, it is known that the bactericidal effectiveness of NaOCl is limited to a depth of 100  $\mu\text{m}$ . However, heavy *E. faecalis* infection was found 800  $\mu\text{m}$  deep into the canal lumen and other bacterial propagation into the dentinal tubules may reach up to 1.100  $\mu\text{m}$  in depth.<sup>12,13</sup>

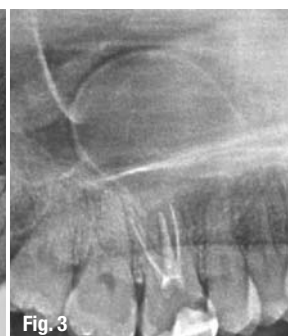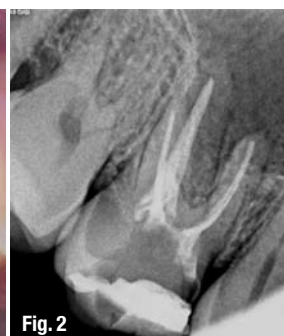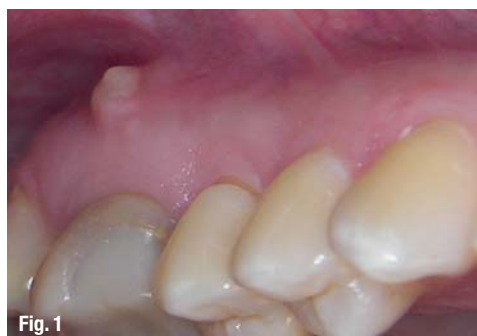During canal enlargement proceedings, a smear layer is mechanically produced, covering the instrumented walls of the main root canal. Together with the possibility that the smear layer itself may be infected, it can also protect the bacteria harbored in the dentinal tubules by reducing root dentin permeability from 25% to 49%.<sup>14</sup> Hence, it is generally accepted that the complete removal of the smear layer would be consistent with the elimination of irritants from the root canal system.<sup>15</sup>

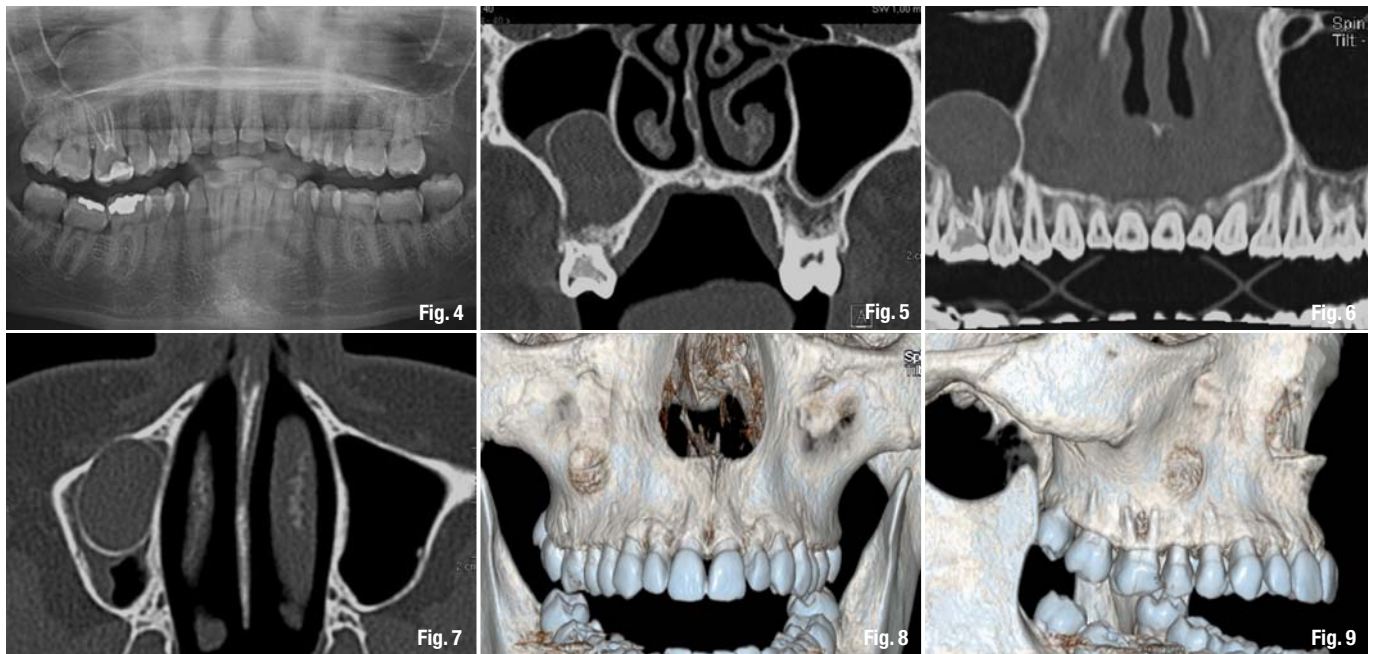
Whether adequate microbial control can be obtained in one appointment is an ongoing source of controversy. Although there are multiple scientific arguments to prefer multiple appointments in root canal therapy of infected teeth with apical periodontitis, clinical research to date has been equivocal.<sup>16,17</sup> Although calcium hydroxide paste is one of the most commonly used intracanal medications for multiple appointment root canal therapy, its effectiveness against several microorganisms commonly associated with persistent apical periodontitis remains questionable.<sup>18,19</sup>

Though, newer treatment strategies designed to eliminate microorganisms from the root canal system should be considered in order to penetrate the dentinal tubules and destroy the microorganisms beyond the host defense mechanisms. Alternative possibilities such

**Figs. 1 & 2** Initial clinical aspect and X-ray of the tooth 1.6 with an active fistula.

**Figs. 3 & 4** Initial panoramic view.





**Figs. 5–7**\_Initial CT scan.  
**Figs. 8 & 9**\_Initial CT scan with three-dimensional reconstruction showing bone fenestration and sinus tract.

as ozone treatment, ultrasonic and laser-assisted treatments are being suggested as suitable methods to achieve endodontic disinfection, possibly overcoming the limitations of commonly used chemical solutions as well as any hazardous effects.<sup>20–23</sup>

The goals for the adjunctive application of erbium lasers in root canal therapy are: the ability of infrared light to interact with water and efficiently remove the smear layer and debris from the root canal walls, together with the ability of light to propagate into the dentinal tubules further than any chemical solution, providing deep disinfection.<sup>24</sup>

The goal of Er,Cr:YSGG laser-assisted endodontic treatment (LAET) is to provide successful long-term outcomes, namely in cases of persistent infections or per-operative obstacles (e.g. isthmus, recurrent canals, internal resorptions, root canal perforations, or wide apical constrictions) which are often associated to either lower or compromised clinical expectations.

### **Chronic apical periodontitis and apical cysts**

Following the formation of a periapical inflammatory lesion secondary to pulpal necrosis, chronic apical periodontitis (granuloma) is considered the next step in the progression of these inflammatory events showing the replacement of adjacent tissue by inflammatory cells, typically containing fibrous tissue and cholesterol crystals.<sup>25</sup>

Over time, due to inflammatory stimulation and proliferation of the epithelial rests of Malassez, an inflammatory cyst can develop around the root apex and

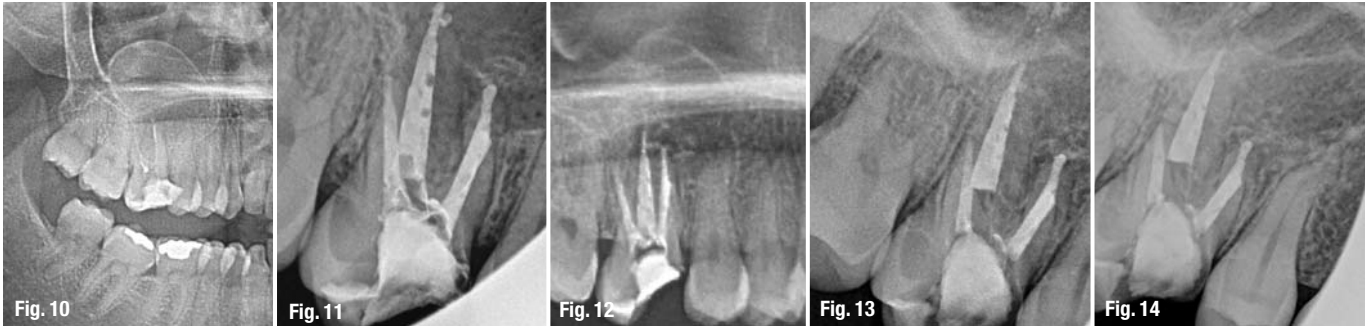through the bone. If the lumen of the cyst is continuous with the infection source at the pulpal entry, it may not be a self-sustained ("pocket" cyst); this will heal following infection source elimination. On the other hand, if the cyst is completely encased by epithelium and removed from the source of infection, it may be a self-sustained ("true" cyst) and become refractory to treatment except by surgical excision.<sup>26</sup>

Cysts mostly appear as round or pear-shaped, unilocular, radiolucent lesions in the periapical region. They are usually classified when they become bigger than 1 cm in diameter, being bordered by a thin rim of cortical bone. Cysts may displace adjacent teeth or cause mild root resorption.<sup>27</sup>

The differentiation between radicular cysts and granulomas is difficult or impossible by traditional radiographic techniques, even if several radiographic features have been proposed to make this distinction. These may include the lesion size and the presence of a radiopaque rim lining the cystic lesion. While the probability of a lesion being a cyst may increase with its size, a reliable diagnosis still remains based on histology.<sup>28,29</sup>

Although being very prevalent, the location of periapical lesions in the oral cavity was found quite similar in different populations. The majority is found in the anterior maxilla (46,5–47,3%) followed by the posterior maxilla (20,7–28,7%), posterior mandible (15,3–18,3%), and anterior mandible (8,7–14,3%).<sup>30,31</sup>

The stages in development and healing of chronic apical periodontitis, granulomas and cysts are, depending on several circumstances, reflected by changes in the radiographic appearance of periapical areas. Gener-



**Fig. 10** Intermediate panoramic view, after gutta-percha removal.

**Fig. 11** Final X-ray.

**Fig. 12** Ten months follow-up.

**Figs. 13 & 14** Two years follow-up.

ally, the prognosis for complete healing of endodontically treated teeth with diagnosis of apical periodontitis is approximately 10%–15% lower than teeth without apical periodontitis.<sup>32,33</sup> Thus, if with ideal conditions for root canal therapy the success rate can reach over 90%, for teeth with periapical radiolucencies, the success rate can decrease to 80%.<sup>34</sup> So, it may be considered that the real challenge for endodontists is to achieve the disinfection of the complete root canal system in teeth associated with chronic apical periodontitis.

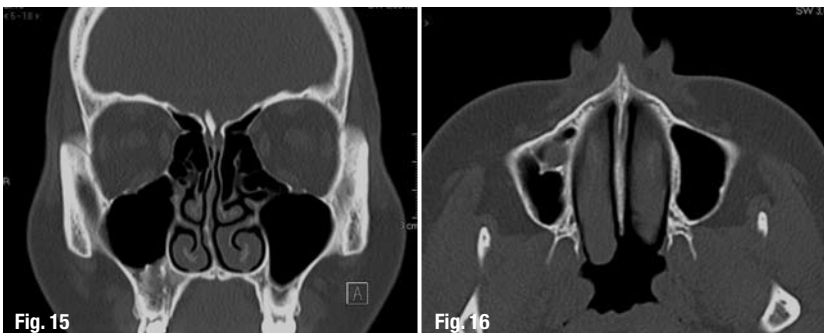### The role of Er,Cr:YSGG laser in endodontics

The rapid development of laser technology as well as a better understanding of laser interaction with biological tissues has broadened the spectrum of possible laser applications in endodontics. The development of new delivery systems, including thin and flexible fibers as well as newly designed endodontic tips, has enabled the use of this technology in almost all range of endodontic procedures.

According to the wavelength and tip configuration, they are applied to disinfect strongly curved root canals and those susceptible to small enlargement. Due to either absorption or transmission properties in dentin, laser energy was found to be still effective in deep dentine layers adjacent to the canal lumen as well as in periapical regions.<sup>35,36</sup>

**Figs. 15 & 16** Two years follow-up CT scan.

Generally, lasers may be especially recommended in the following situations: teeth with purulent pulpitis or



**Fig. 15**

**Fig. 16**

pulp necrosis, periapical lesions, abscesses, lateral canals, reabsorption of the apex caused by inflammation or trauma and for teeth retreatments with low prognosis of success.

The Er,Cr:YSGG laser shows high absorption coefficients in hydroxyapatite and water so that germ reduction would theoretically take place predominantly in the main canal(s). However, apart from being useful to remove organic tissue and smear layer through cavitation effects, researchers reported that dentinal tubules may act as light optical conductors and therefore erbium lasers could still be considered effective for root canal disinfection up to a depth of 500 μm.<sup>35</sup>

Although *in vitro* investigations may support the use of Er,Cr:YSGG laser in endodontics, few clinical trials have been reported regarding the potential benefits and long-term outcomes after such treatments.<sup>24</sup>

### Radial firing tips

Up to now, endodontic fibers have bare tips so the energy is transmitted forward with a relatively small divergence. This limitation required the clinician to move the fiber in a withdrawing and rotating action in order to attempt a uniform coverage of the root canal walls. Thus, with bare fibers, it was found almost impossible to obtain uniform coverage of the canal surface along with reproducible results.<sup>37</sup>

The direct emission of the laser from the tip of the optical fiber near the root end may also result in the transmission of the irradiation beyond the apical foramen leading to undesirable effects on either teeth in close proximity to the mental foramen or the mandibular nerve.<sup>38</sup> Most lasers have then commonly reported disadvantages: (1) most of the laser energy is directed only in the axial direction, and little energy can be obtained perpendicular to the fiber; and (2) many wavelengths cannot eliminate the smear layer and the bacteria in the root canal wall, making the use of lasers less applicable.

To overcome concerns related to the energy emission in axial direction and not towards the canal wall, the unique emission profile obtained for the Er,Cr:YSGG

laser radial firing tips (RFT) played a significant role in increasing the efficiency of laser delivery for endodontic application. Not only does the beam expansion by the tip geometry reduce emissions in the forward direction, but it favours homogeneous energy distribution along the root canal wall.<sup>39,30</sup>

The debriding action of a laser in endodontics has shown to be better when delivered through conical fibers than with bare fibers as the divergent laser energy will interact with the canal walls, causing direct and indirect ablation through photomechanical effects. In fact, erbium lasers have been demonstrating to induce shock waves in aqueous solutions inside root canals and radial firing tips positively influence their configuration. Hence, through the activation of aqueous solutions (e.g. water, EDTA) the Er,Cr:YSGG laser induces primary and secondary cavitation effects, useful for debris and smear layer removal.<sup>41-44</sup>

However, the best results in terms of thorough root canal disinfection with the Er,Cr:YSGG laser are achieved while operating in dry conditions, relying on the fact that—without water inside the main root canal—the ability of such wavelength to penetrate into the dentinal tubules is increased.<sup>35,40</sup> Today, limited literature addresses the clinical outcome of en-

dodontic therapy using RFTs without the aid of any chemical substances.<sup>24</sup> This clinical case study aims to represent an interesting proof of concept for the benefits of using radial firing tips in highly compromised teeth with apical pathology.

### Clinical case

A female patient (S.F.), 33 years old, presented a history of recurrent sinusitis and multiple antibiotic administrations. A previous endodontic treatment was performed within the past two years. At this time, she was referred by her dentist to an oral surgeon for cyst ablation and tooth extraction under general anaesthesia. An active fistula on the apical-buccal area of the tooth 1.6 was detected; vertical percussion was also found positive (Fig. 1). A non-surgical laser-assisted endodontic retreatment was proposed prior to surgery for cyst ablation. A written informed consent was previously signed. The endodontic retreatment was performed in two appointments according to the protocol described in Martins et al.<sup>24</sup> During the first appointment, initial carious excavation was performed and the resin filling was removed. Rubber dam isolation was obtained and the access cavity prepared. The working length (WL) was electronically established as 1 mm short of the biological apex of the root.

AD



DENTAL TRIBUNE  
**DT STUDY CLUB**  
COURSES | DISCUSSIONS | TECHNOLOGY | ON-DEMAND

[www.DTStudyClub.com](http://www.DTStudyClub.com)

## Live, Interactive Webinars and On Demand Courses

A growing education platform where you can find more than 400 dental courses, live Webinars, live Education Symposia.

### Interested in C.E. credits? and quality learning?

Learn from the experts:

Richard Niederman  
Louis Malcmacher  
Eduardo Mahn  
Robert Horowitz  
Paul Weigl  
Shamshudin Kherani  
Christian Coachman  
Ron Kaminer

Edgar Garcia Hurtado  
Glenn van As  
Marc Gottlieb  
John Fluke  
Marius Steigmann  
David Hoexter  
Dwayne Karateew  
Fotinos S. Panagakos

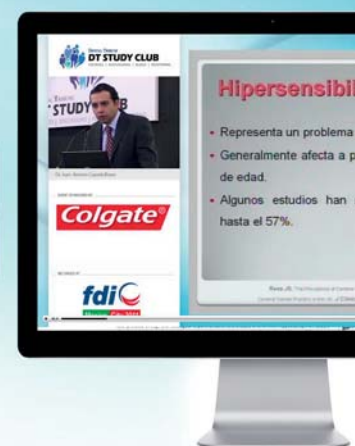
### Interested in sponsoring education?

Some of our partners:



**"83% of the dentists visited the exhibiting sponsors as a result of attending the Symposia."**

*this is what we've learned from our customers*



Register for FREE on [www.DTStudyClub.com](http://www.DTStudyClub.com)

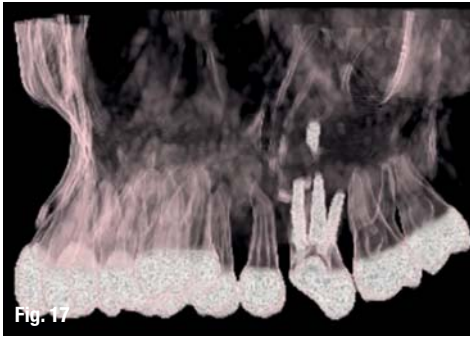


Fig. 17

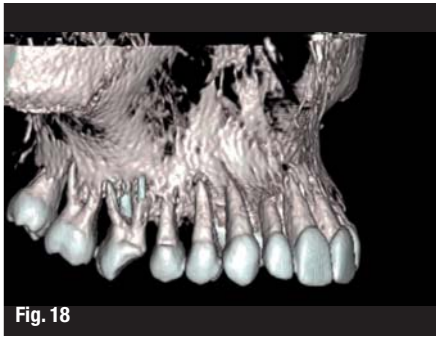

Fig. 18

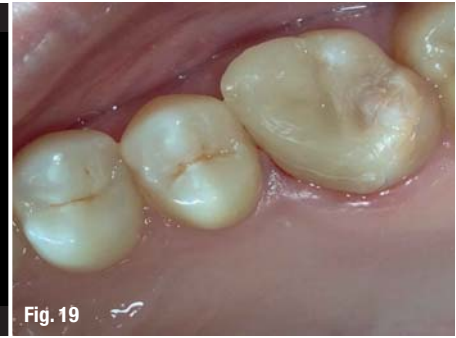

Fig. 19

**Figs. 17 & 18** Two years follow-up CT scan with three-dimensional reconstruction.

**Fig. 19** Two years follow-up clinical aspect.

Desobturation and root canal preparation were performed with both ProTaper® retreatment and treatment files respectively (DENTSPLY Maillefer, Switzerland). Both Mesio-Buccal and Disto-Buccal canals were prepared up to a #F3 file, while the palatal canal was prepared up to an #F4 file. Irrigation was performed with 2.0 ml of saline solution between files. After root canal enlargement, the main canals were filled with distilled water and laser irradiation was performed with the 2,780 nm Er,Cr:YSGG laser (Waterlase MD; Biolase Technology, Inc, San Clement, CA) and a 270 µm in diameter radial firing tip (RFT2 Endolase, Biolase Technology, Inc; calibration factor of 0.55) with panel settings of 0.75 W, 20 Hz (37,5 mJ), 140 µs pulse, 0% water and air. The tip was placed at the working length and irradiation was performed approximately at the speed of 2 mms<sup>-1</sup> until the most coronal part of each canal was reached.

The irradiation procedure was repeated four times (two with the canal filled with distilled water and two in dry conditions), resting approximately 15 seconds between each irradiation. This protocol was described by Martins et al.<sup>2</sup> Finishing the first appointment, a sterile cotton pellet was placed in the pulp chamber, and the access cavity was sealed with a reinforced zinc-oxide eugenol intermediate restorative material (IRM—intermediate restorative material, DENTSPLY). On the second appointment, which took place 15 days after the first visit, the patient was inquired for symptoms history such as pain, sensitivity to percussion, or swelling. As none of these clinical conditions were registered, apical patency was confirmed, the main canals were filled with distilled water and laser irradiation was now performed with a 320 µm radial firing tip (RFT3 Endolase, Biolase Technology, Inc; calibration factor of 0.85) with panel settings of 1.25 W, 20 Hz (62.5 mJ), 140 µs pulse, 0% water and air. The irradiation protocol was identical to the first appointment.

After irradiation, canals were irrigated with 5.0 ml of saline solution during approximately 1 minute of final rinsing and dried with sterile paper points, checking for the absence of any suppuration or exudate. Root canals were filled with a single gutta-percha tapered cone technique, a resin-based sealer (TopSeal, DENTSPLY) and vertical compaction.

## Discussion and conclusion

To adopt a single wavelength treatment protocol that more reliably renders root canals free of smear layer and bacteria before filling seems interesting. This could be an additional clinical evidence to suggest that the Er,Cr:YSGG laser with radial firing tips could be a valuable strategy to (1) remove smear layer in wet conditions and (2) achieve deep disinfection in dry conditions, within the same protocol.

While clinical as well as radiographic data can be used to access treatment outcomes, the relative absence of clinical symptoms in CAP makes the assessment primarily a radiographic one. As a consequence, in endodontic controlled clinical studies, data generated by radiographic means are often used.<sup>45</sup> Furthermore, this clinical report has shown that, presumably, even apical cysts could be successfully treated by endodontic means, by using a 2,780 nm wavelength and radial firing tips. The Er,Cr:YSGG laser should be considered a predictable tool to assist endodontic treatments overcoming possible limitations commonly associated to conventional strategies. However, few clinical trials and single-reports have been reported. This clinical case should stimulate either researchers to conduct additional blind randomised trials or clinicians to report their clinical findings in order to provide an evidence-based concept for the use of radial firing tips in endodontics.

*Editorial note: A list of references is available from the publisher.*

### contact

laser

#### Miguel Rodrigues Martins

DDS, MSc

Endodontic Department, Faculty of Dental Medicine, Universidade do Porto – Portugal  
Rua Dr. Manuel Pereira da Silva, 4200-393 Porto  
PORTUGAL

Tel.: +351 914610046

miguel.ar.martins@gmail.com

# dental tribune istanbul



## ISTANBUL WELCOMES DENTAL PROFESSIONALS

22 International Speakers

Lectures on implantology, oral surgery, aesthetics, endodontics, laser dentistry

Workshop / Live demonstrations

Hands-on courses

Visit free exhibition area on 2.500 sqm

Enjoy open buffet lunch from the chef masters

Online congress booking is available at

[dentalistanbul.com](http://dentalistanbul.com)

To book your booth please contact [derya.arslan@vyg.com.tr](mailto:derya.arslan@vyg.com.tr)

**di** **DENTAL  
ISTANBUL'13**  
ARALIK / DECEMBER 07-08, 2013  
GRAND CEVAHİR KONGRE MERKEZİ

**dti** Dental  
Tribune  
International

**vyg**  
vestiver  
publishinggroup

# Er:YAG laser in the bonding and debonding steps of orthodontic treatment

Author\_Prof. Carlo Fornaini, Italy

## \_Introduction

The Er:YAG laser was first proposed in 1990 by Hibst and Keller to ablate hard dental tissues. Today it is employed in conservative dentistry as an alternative to rotating instruments.<sup>1,2</sup> A study based on patient questionnaires demonstrated that, in terms of satisfaction, Er:YAG dental treatment represents an effective technique that may improve patient cooperation and diminish fears associated with the dental office, particularly in pediatric patients.<sup>3</sup> This is also a reason to suggest its application in the field of orthodontics, where cooperation and good relationships between the patient and operator are strictly necessary for full success of a treatment. In this paper we describe the utilisation of the Er:YAG laser in the bonding and debonding steps of orthodontic treatments.

## \_Enamel preparation

Proper conditioning of the enamel surface is necessary for the bonding of orthodontic attachments to teeth. In orthodontics, as in other fields of dentistry, the most common method of enamel preparation is acid phosphoric etching. The acid etching process prepares the surface by selective removal of inter-prismatic mineral structure, while organic materials are less affected.

The resultant rough and micro-fissured surface is very useful for the retention of adhesive resins, but these structures are also more vulnerable to caries formation. Acid etching removes and demineralises the most superficial and protective layer of enamel and makes the teeth more susceptible to long-term acid attack, especially when

- Fig. 1\_Non-treated enamel.
- Fig. 2\_Acid-treated enamel.
- Fig. 3\_Laser-treated enamel.
- Fig. 4\_Before the irradiation: the center is marked on each tooth.
- Fig. 5\_The screen positioned on the tooth.
- Fig. 6\_Irradiation of the tooth.




Fig. 1




Fig. 2




Fig. 3

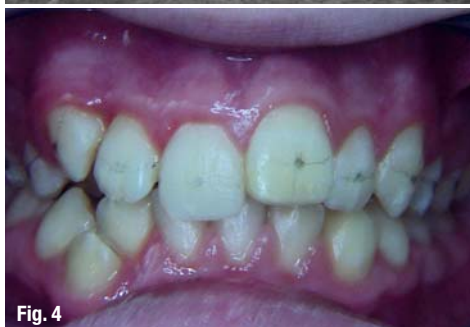

Fig. 4

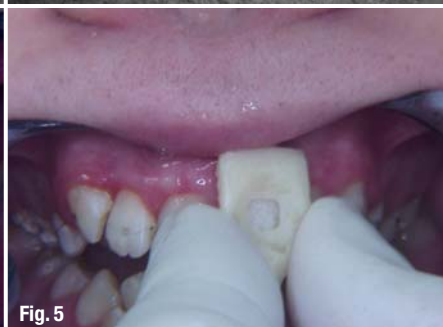

Fig. 5

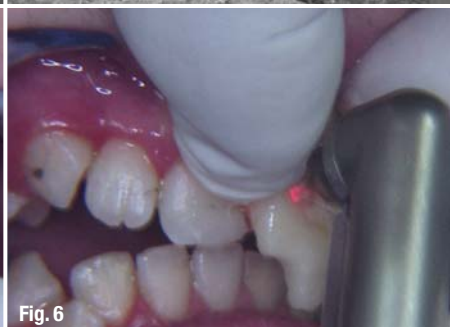

Fig. 6



Under the Patronage of  
**H. H. Sheikh Hamdan Bin Rashid Al Maktoum**  
Deputy Ruler of Dubai, Minister of Finance  
President of the Dubai Health Authority

تحت رعاية  
سمو الشيخ حمدان بن راشد آل مكتوم  
نائب حاكم دبي، وزير المالية  
رئيس هيئة الصحة بدبي

## مؤتمر الإمارات الدولي لطب الأسنان ومعرض طب الأسنان العربي UAE INTERNATIONAL DENTAL CONFERENCE & ARAB DENTAL EXHIBITION

# إيكد AEEEDC DUBAI

Delivering Science & Technology

4 - 6 February, 2014

مركز دبي الدولي للمؤتمرات والمعارض  
Dubai International Convention & Exhibition Centre

[www.aeedc.com](http://www.aeedc.com)

Organised by



In Cooperation with



Strategic Partner

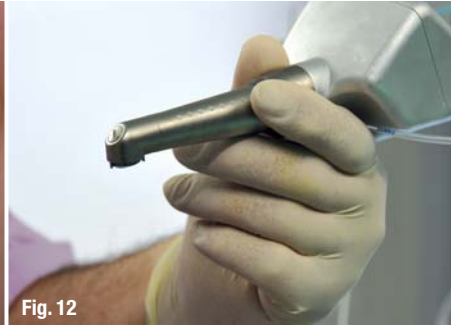
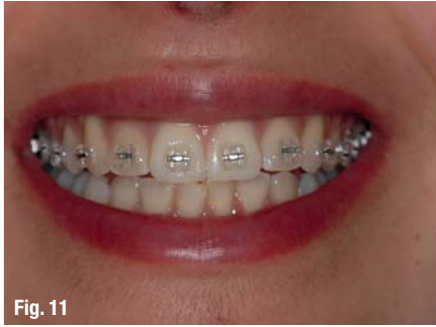
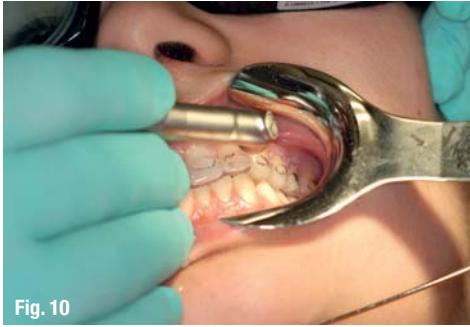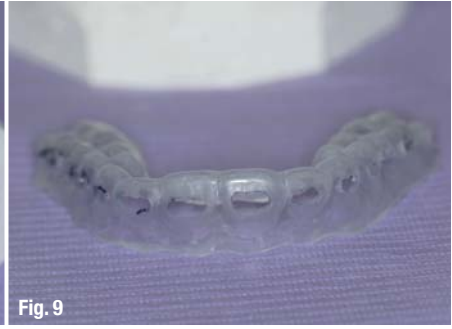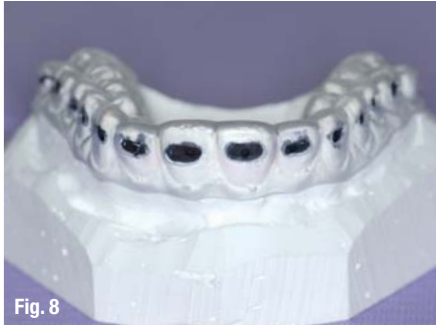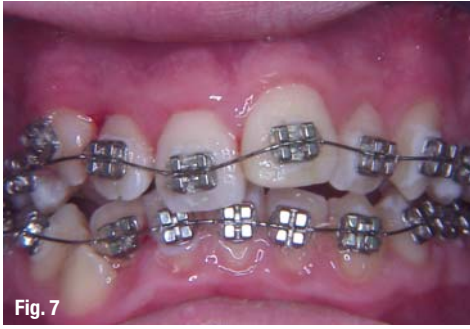Supported by



**INDEX® Conferences & Exhibitions Organisation Est.**

Dubai Healthcare City, Ibn Sina Medical Complex #27, Block B, Office 203 | P.O. Box: 13636, Dubai, United Arab Emirates  
Tel: +971 4 3624717, Fax: +971 4 3624718 | E-mail: [info@aeedc.com](mailto:info@aeedc.com), Website: [www.index.ae](http://www.index.ae)



**Fig. 7\_**Bonding procedure completed.  
**Fig. 8\_** The thermo-formed tray inserted into the model.  
**Fig. 9\_** Thermo-formed tray with holes for laser irradiation.  
**Fig. 10\_** Laser irradiation.  
**Fig. 11\_** Bonding procedure completed.  
**Fig. 12\_** X-Runner, Fotona.

resin monomers cannot sufficiently fill the demineralised area due to saliva contamination or air bubbles.<sup>4</sup> Since the prevalence of white spot lesions is very high among orthodontic patients, the prevention of enamel demineralisation is of great importance in orthodontics.<sup>5</sup>

There has been extensive research to find an alternative conditioning method to overcome the main disadvantage of phosphoric acid etching, i.e. the potential for producing decalcification. Some researchers have worked on conditioning enamel with poly-acrylic acid or pre-treatment of the enamel surface with a sandblast of aluminium ox-

ide to reduce the rate of enamel loss during etching,<sup>6,7</sup> however, these methods failed to achieve adequate bond strength to resist intraoral forces.<sup>8</sup>

### Laser in orthodontics

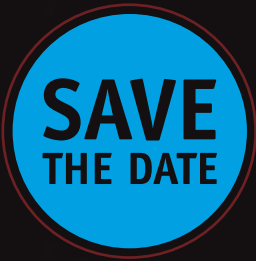Er:YAG laser preparation has become one effective alternative to acid etching of enamel. Laser etching is painless and does not involve either vibration or heat; also, the easy handling of the apparatus makes this treatment highly attractive for routine clinical use.<sup>9</sup>

The employment of a laser with orthophosphoric acid etching to enhance the strength adhesion of composite resins has been proposed by several authors in conservative dentistry, as well as for bracket bonding in orthodontics.<sup>10</sup> An *in vitro* study at our university<sup>11</sup> on 36 human extracted molars, divided into three groups on the basis of enamel conditioning (acid only, laser only and laser plus acid) and analysed by traction tests by measuring the force necessary to detach the brackets, gave the results reported below (Tab.1 and 2).

Recently, another interesting *in vitro* study,<sup>12</sup> based on strength analysis by traction test and morphological analysis by SEM and Atomic Force Microscope, showed the same effects with Er:YAG irradiation alone as with acid etching. This was obtained by using the so-called "QSP" mode (Fotona, Ljubljana, Slovenia) in which each pulse is split into several shorter pulses that follow each other at an optimally fast rate. In this way, a specific surface roughness is achieved, representing a real alternative to acid etching. Microscopic observation of the samples ob-

**Table 1\_** Values (in MPa) of the force necessary to detach the brackets.

	ACID [MPa]	LASER [MPa]	ACID + LASER [MPa]
	11.04	2.34	10.18
	10.58	1.56	9.2
	6.26	8.62	15.1
	9.2	5.92	10.58
	6.86	7.36	16.86
	11.48	4.5	17.84
	5.34	4.3	7.06
	1.98	3.32	13.52
	6.26	5.36	4.5
	7.5	5.08	4.12
	4.78	7.06	7.44
	3.06	4.5	11.36
<b>Media</b>	<b>7.02</b>	<b>4.99</b>	<b>10.64</b>
<b>Dev. Standard</b>	<b>3.07</b>	<b>2.05</b>	<b>4.52</b>



NOVEMBER 15-16,  
2013// BERLIN,  
GERMANY//MARITIM HOTEL

# LASER START UP 2013



# 22nd ANNUAL CONGRESS OF THE DGL e.V.



**DOWNLOAD**  
PROGRAMME AND  
REGISTRATION FORM

SPONSOR



## PLEASE FAX THIS FORM

+49 341 48474-390

Further information about:

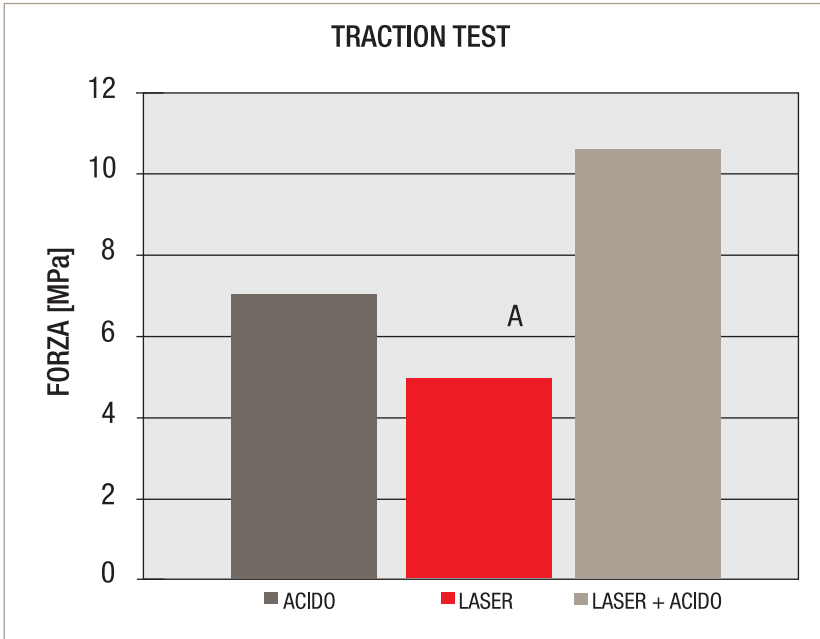
LASER START UP 2013     22nd ANNUAL CONGRESS OF THE DGL e.V

November 15-16, 2013, Berlin, Germany

NAME/E-MAIL

OFFICE STAMP

laser 4/13



**Table 2** Comparison of the three samples groups.

tained by the first study (University of Parma) (Figs. 1–3) demonstrated that the enamel laser irradiation creates micro-fissures that are ideal for resin penetration.<sup>13</sup>

The surface produced by laser irradiation is also acid resistant. Laser irradiation of the enamel modifies the calcium-phosphate ratio and leads to the formation of more stable and less acid-soluble compounds, thus reducing the susceptibility to caries attack.<sup>14, 15</sup>

Because water spraying and air drying are not needed with laser etching, time can be saved.<sup>16, 17</sup> From a clinical standpoint, saving chair time also improves adhesion because it reduces the risk of salivary contamination.

Moreover, other authors have underscored the result by using lasers to prepare the enamel surface to make it more resistant to decay<sup>18</sup> due to the modification of the hydroxyapatite crystals. Additionally, it is very important in the prevention of decalcification zones around the brackets, particularly in patients with scanty oral hygiene.<sup>19</sup>

In recent years, several techniques have been proposed with the same goal: to prepare a very small

surface of enamel, exactly of the same dimension of the bracket, in line with the concept of modern "minimally invasive dentistry".

The first method<sup>20</sup> consisted of the use of a ceramic screen with a central window; the disadvantage consisted of the necessity to move the screen from one tooth to another for irradiation, after first marking the centre of each with a pencil (Figs. 4–7).

Parameters: Laser source: Er:YAG, 2940 nm (Fidelis Plus III, Fotona)  
 Pulse duration: MSP  
 Energy: 80 mJ defocused  
 Frequency: 18 Hz  
 Handpiece: R02, 4/6 water/air spray

An evolution of this technique was performed with the introduction of thermo-formed individual trays,<sup>21</sup> which, after placement into the mouth, allowed for the irradiation of all the teeth of the arch (Figs. 8–11).

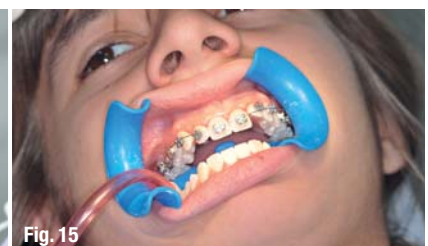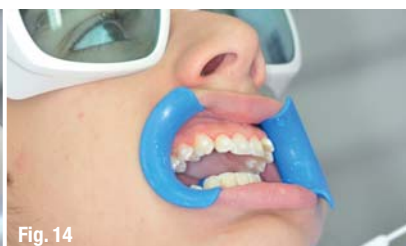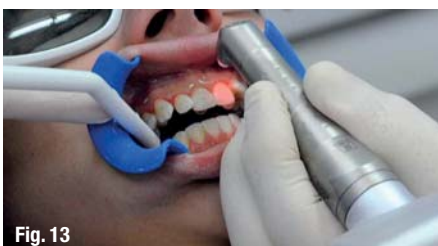Parameters: Laser source: Er:YAG, 2940 nm (Fidelis Plus III, Fotona)  
 Pulse duration: MSP  
 Energy: 80 mJ defocused  
 Frequency: 18 Hz  
 Handpiece: R02-C, 4/6 water/air spray

With the introduction of digitally-controlled technology in laser dentistry, which led to the realisation and commercialisation of the "X-Runner" laser handpiece (Fotona, Ljubljana, Slovenia), the method became significantly easier and faster, without the need to employ screens and/or trays.<sup>22</sup> In fact, using the laser system's touch screen, it is very simple to program the size and dimensions required, and then automatically irradiate an area equivalent to the bracket surface (Figs. 12–14).

**\_Debonding**

Enamel damage, whether in the form of enamel fractures or cracks, detracts from the aesthetics of the tooth and may require costly restorative treatment. It may even compromise the tooth's integrity by increasing the risk of eventual tooth fracture.

**Fig. 13** Irradiation of the central incisor.  
**Fig. 14** Irradiation of the premolars.  
**Fig. 15** Bonding procedure completed.



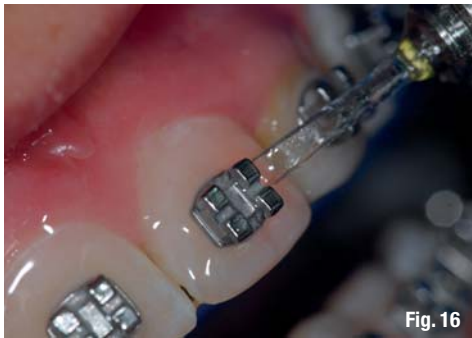

Fig. 16

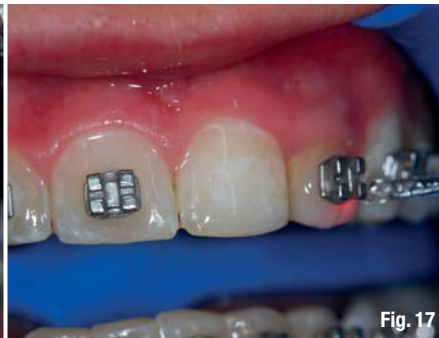

Fig. 17

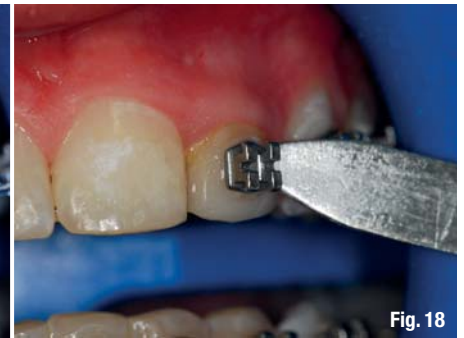

Fig. 18

When the required force for bracket removal exceeds the cohesive strength of the enamel, fracture of the enamel surface is inevitable. With the introduction of ceramic brackets in the mid-1980s, the problem became more important: in fact, the low fracture toughness of ceramics may cause partial or complete bracket fracture during removal. This precludes reuse of the same bracket at a corrected position and may result in eye damage, ingestion or aspiration of bracket fragments. In addition, removal of a bracket fragment on the tooth may require the use of diamond burs, a process that is time consuming and can damage the pulp and enamel surface.<sup>23, 24</sup>

Since the early 1990s, lasers have been used experimentally for the debonding of ceramic brackets. The use of lasers eliminates problems such as enamel tear outs, bracket failures, and pain that are encountered during conventional ceramic bracket removal techniques.<sup>25</sup>

Additionally, lasers have the advantage of decreasing the debonding force and operation time. In most previous studies, carbon dioxide lasers, whose wavelength is more easily absorbed by the ceramic brackets, had been preferred for debonding.<sup>25</sup> In others,<sup>26</sup> Nd:YAG was proposed, although with this wavelength, approximately 69–75% of the incident light reached the enamel surface, which has the potential to cause pain or damage to the tooth structure.

Oztoprak et al. preferred the Er:YAG laser since it has a lower thermal effect than the Nd:YAG or CO<sub>2</sub> lasers. They stated that the Er:YAG laser is effective for reducing the shear bond strengths of orthodontic polycrystalline ceramic brackets from high values to levels that are safe for removal from the teeth.<sup>27</sup>

All these methods described are based on thermal softening of the resin by the beam, but are active only in the case of ceramic brackets. The technique we propose may be used both on ceramic and metallic brackets, and consists of the utilisation of a H14-C handpiece with chiselled fiber tip

(LightWalker AT, Fotona, Ljubljana, Slovenia). It is assumed that the vibrations produced by the photo-mechanical effects of this wavelength play the main role in the process of bracket detachment.

The fiber tip is placed tangentially to the crown surface and inserted between bracket and enamel as close to the metal bracket as possible at a 45 degree angle. This way, the laser energy is directed to the adhesive. Ten laser pulses are delivered at each side of the bracket. After that, the metal bracket is removed, with a very low strength, with the help of a spatula normally used to mix the cement. In this way, there are no complications during the debonding procedure and no damage to the enamel surface. As the energy is set relatively low in MSP mode, there is also no danger for intra-pulpal temperature rise. Patients report absolutely no stress during the procedure (Figs. 16–18).

Parameters: Laser source: Er:YAG, 2,940 nm  
(LightWalker AT, Fotona)  
Pulse duration: MSP  
Energy: 80 mJ  
Frequency: 10 Hz  
Handpiece: H14-C with chiseled fiber tip,  
4/6 water/air spray

*Editorial note: A list of references is available from the publisher.*

**\_contact**

**laser**

**Prof. Dr Carlo Fornaini**

MD, DDS, MSc  
Dental School, Faculty of Medicine,  
University of Parma,  
Via Gramsci 14  
43126 Parma, Italy

Tel.: +39 0521 292759  
Fax: +39 0523 986722

info@fornainident.it  
www.fornainident.it

# The efficacy of combined low intensity laser therapy and medication on xerostomia

**Authors**\_Dr Sawanya Taboran & Assoc. Prof. Dr Sajee Sattayut, Thailand

## Abstract

Xerostomia causes patient suffering from the limitation of daily life activities. Still, there has been no definite treatment for this, particularly its variant induced by aging. This case report presents the method of treating xerostomia using low intensity laser therapy and medication.

## Introduction

Xerostomia is an oral symptom of dry mouth, which is a major complaint of many elderly individuals. It results in impaired food and beverage intake, altered taste, difficulties in eating, chewing and swallowing, which can affect the quality of a person's life. Although suffering patients seek medical help, it usually provides no adequate re-

lief.<sup>1</sup> Not many patients were able to tolerate the strange taste of artificial saliva or the side effect of sweating from taking pilocarpine; a medication for activating salivation. Symptomatic treatment by using saliva substitute for moistening and lubrication of the oral mucosa was the only management for this condition. But is there a different, the non-invasive method that could be used for treating xerostomia?

In 2010, Kato et al. conducted a pilot study proving a significant and lasting reduction in burning mouth symptoms from the group treated by low intensity laser therapy (LILT).<sup>2</sup> In the same year, Vidovic Juras et al. reported an application of LILT to xerostomia patients' major salivary glands to stimulate salivation.<sup>3</sup> This report presents a combined medication and LILT for treating xerostomia with satisfactory results.

## Case report

A 60-year-old woman had suffered from oral dryness interfering with her life style daily for three years. There had been no therapy including vitamin supplement and more water intake to relief these symptoms.

### *Past medical history*

The patient suffered from anaemia due to nutritional deficiency. She was treated by taking ferrous sulphate and folic acid. Her menopause had started about ten years ago. She was allergic to penicillin, pollen and adverse weather. The patient took an antihistamine agent, Zyrtec, one tablet per day.

### *Oral examination*

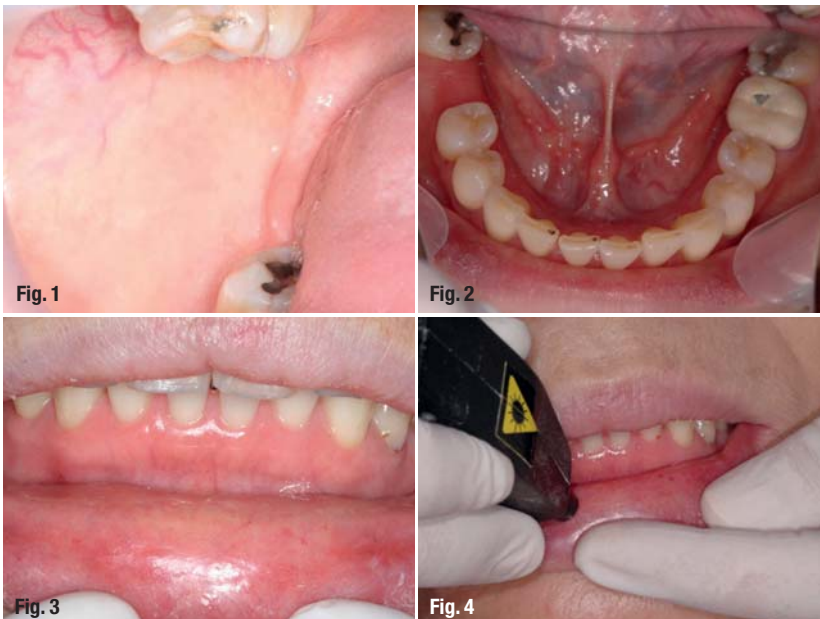Extraoral examination showed a dry and cracked lower lip. Intraoral examination found dryness of

**Fig. 1**\_Dry buccal mucosa observed in the first visit.

**Fig. 2**\_Dried floor of the mouth observed in the first visit.

**Fig. 3**\_After the first episode of LILT, still some erythematous areas in vermillion border of the lower lip are observed in the first visit.

**Fig. 4**\_LILT irradiating to the vermillion border of lower lip.



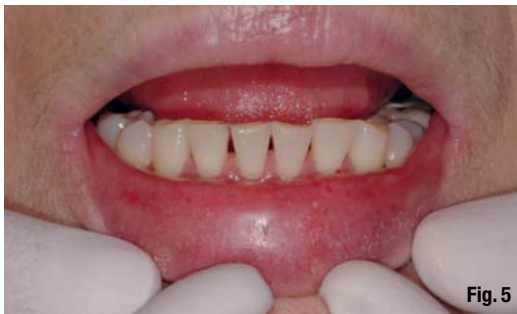

Fig. 5

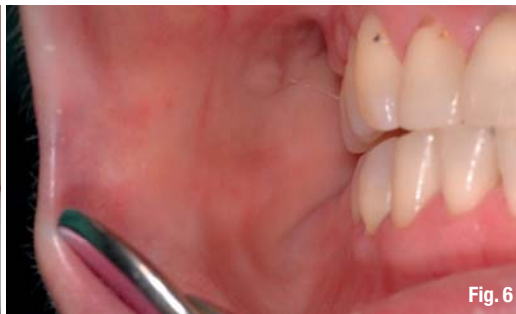

Fig. 6

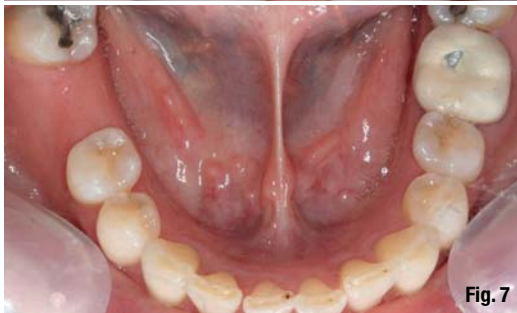

Fig. 7

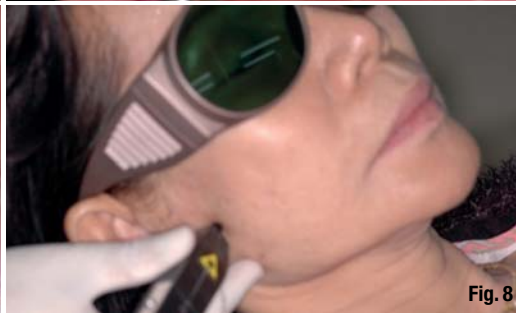

Fig. 8

**Fig. 5** After ten LILT sessions; remarkably less erythematous areas are observed in the vermilion border of lower lip.

**Fig. 6** Moist buccal mucosa observed during the tenth visit.

**Fig. 7** Moist floor of the mouth observed in the tenth visit.

**Fig. 8** LILT irradiation of the skin above the parotid gland area.

the oral mucosa (Fig. 1), including the floor the of mouth (Fig. 2), atrophic tongue and erythematous at the vermilion border of the lower lip with biting from the lower anterior teeth (Fig. 3).

*Treatments and their results*

The first visit:

Treatment: Zyrtec was limited. The patient was advised to sip water as necessary.

Result: Two weeks later, the patient could sense moisture in the oral cavity and dysphagia less pronounced. Intraoral examination found a significant amount of saliva in comparison to the last visit.

Impression: Drug-induced xerostomia.

The second to the tenth visits (one treatment session per week): Erythematous sections at the vermilion border of the lower lip were treated with low intensity laser (Fig. 4), 820 nm, 100 mW, 2J, 20 seconds, continuous wave for 18 points. Vitamin C and B complexes were prescribed.

Result: The patient was more satisfied with the result after the second treatment session with LILT. The moist lip (Fig. 5), oral mucosa (Fig. 6) and floor of mouth (Fig. 7) were observed. Less erythematous areas were noticed at the vermilion border of the lower lip after the second time of treatment with LILT. They disappeared after the tenth visit.

The sixth to eleventh visits: Low intensity laser therapy 820 nm, 100 mW, 2J, 20 seconds, continuous wave for 22 points in the left and right parotid gland area (Fig. 8).

Result: There was an increase in the whole stimulated salivary flow rate from 0.06 ml/min in the first visit to 0.08 ml/min after the second treatment and 0.10 ml/min after the fourth treatment.

**\_Discussion**

The satisfying clinical outcome of treating xerostomia and atrophic mucosa caused by aging and side effects of drugs was found by using combined medications and LILT. LILT can be used to reduce burning mouth symptoms and to stimulate major salivary glands to produce more saliva. This can be explained by the effect of LILT for biomodulation in terms of initiating healing mechanism and immune response.<sup>4</sup>

**\_Conclusion**

This case report has shown that using vitamin C and B complex supplements combined with low intensity laser therapy can improve the clinical impairment of xerostomia and can also increase saliva secretion in elderly patients.

<b>_contact</b>	<b>laser</b>
<p><b>Assoc Prof. Dr Sajee Sattayut</b>                  Chairman of Lasers in Dentistry Research Group                  Faculty of Dentistry                  Khon Kaen University, Khon Kaen City, 40002                  Thailand</p> <p>Tel.: +66 815442460                  Fax: +66 43348153</p> <p>sajee@kku.ac.th</p>	

# A combined device for optimal soft tissue applications in laser dentistry

**Authors** Hans J. Koort, Dr Michael Hopp, Germany & Prof. Dr D. Gabrić Panduric, Croatia

## \_Introduction

The use of alternating electric current for bloodless interventions in the oral soft tissues has been established for nearly a century, first in the form of the electric knife (cauter), then later as radiofrequency devices. Laser devices were introduced in the 1980s as new, additional tools and they have strongly gained in importance today. One particular question often emerges: What are the similarities between diode lasers and radiofrequency generators and what makes them different? What is their value for dental applications?

## \_Similarities

The laser light as well as the electric current of the radiofrequency device make use of the spatially concentrated and very fast heating of cells in the tissue. Thus they both are able to cut and coagulate in a precise way. Bleeding is stopped with high efficacy, allowing the surgeon a clear view of the surgical field.

## \_Differences

While the laser radiation is passed through an optical fiber and emits from the fiber tip to the tissue surface, the radiofrequency current is directed

through a metal electrode into the tissue. The main difference: A priori, the laser fiber can not be inserted deeply into the tissue to produce a cut. The laser radiation emits from the front end of a fiber and thus heats only the uppermost layer of the tissue and ablates it. Therefore, the tissue must be removed in a layer-by-layer procedure to get into the depth.

In contrast, the metal electrode of a radiofrequency device can be inserted into the tissue in one step in an intended depth. The radiofrequency current heats the targeted area simultaneously and uniformly to the entire physical length of the electrode. It allows a one-step precise, stressless and almost athermic procedure with an excellent tactile feel. The cutting speed especially in larger and deeper areas is much faster than with a laser.

In intraoral use, the radiofrequency technology is positively received because the local increase in temperature is less than 60 to 80 °C. Using a laser or an electric knife, respectively, a temperature increase of more than 400 °C must be considered.

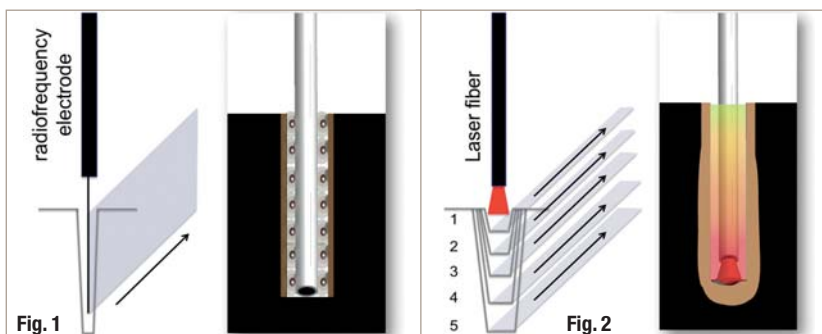
## \_Useful applications

The strength of a laser lies in the treatment of superficial soft tissues, such as the removal or reshaping of thin skin layers: i.e. exposure of overgrown implants, gingiva streamlining, in periodontic treatments, in endodontics as well as in special applications like bleaching, photodynamic therapy (PDT) and low level laser therapy (LLLT).

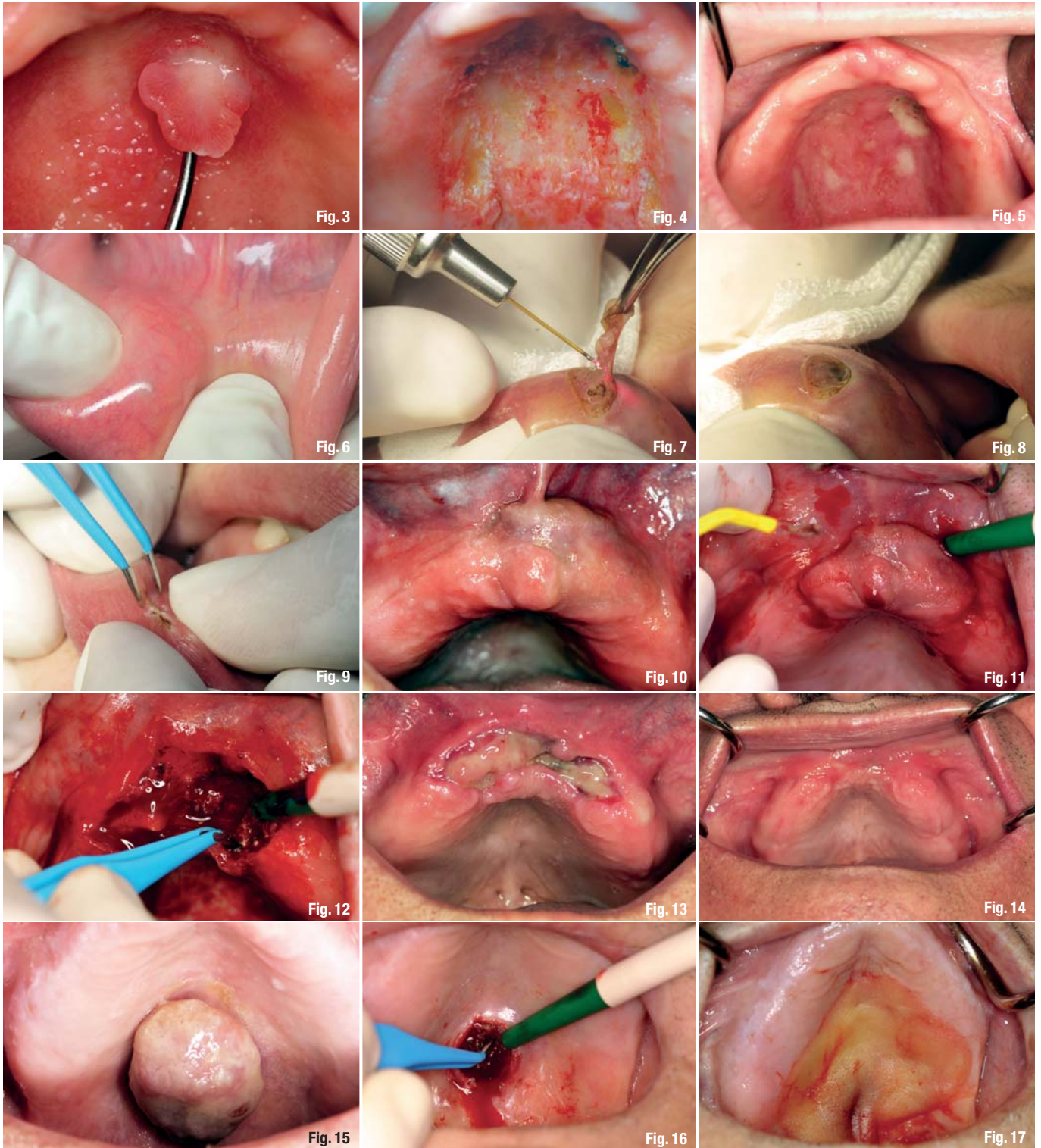
A significant disadvantage, however, can be seen in deeper surgical applications. The oral tissue is very thin, it is delicate and has complicated structures and in addition it usually is in close proximity to jaw bones and tooth structures. Laser radiation

**Fig 1** Cutting of tissue with radiofrequency: The tissue is removed with only one precise, uniform cut in the entire length of the inserted electrode. The metal electrode remains cold at its frequency of 2.2 MHz.

**Fig. 2** The cutting process with a laser is a layer-by-layer removal of superficial tissue.







**Fig. 3** Clinical appearance of the palatal fibroepithelial polyp and inflammatory papillary hyperplasia of the hard palate.

**Fig. 4** Immediate postsurgical view.

**Fig. 5** Follow up, third day after surgery.

**Fig. 6** Clinical appearance of the mucocele at the lower lip, before surgery.

**Fig. 7** Surgical procedure performed using diode laser.

**Fig. 8** Immediate postsurgical view.

**Fig. 9** Closing of the incision lines with bipolar forceps using radiofrequency technology.

**Fig. 10** Clinical appearance of the maxillary giant cell granuloma.

**Fig. 11** Removal of giant cell granuloma with radiofrequency.

**Fig. 12** Bleeding control using bipolar forceps immediately after excision.

**Fig. 13** Follow-ups, two weeks after surgery.

**Fig. 14** Follow up, five weeks after surgery.

**Fig. 15** Clinical appearance of metastasis at the hard palate.

**Fig. 16** Immediate postsurgical view, bleeding control using bipolar forceps.

**Fig. 17** Wound covered with a dressing.

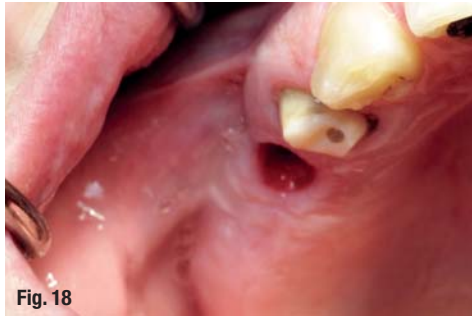

Fig. 18

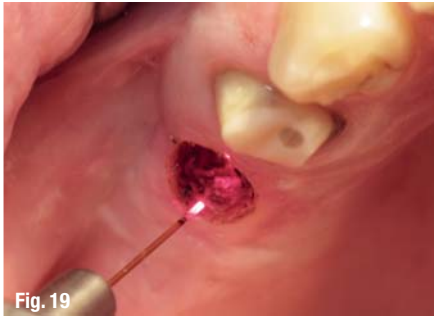


Fig. 19

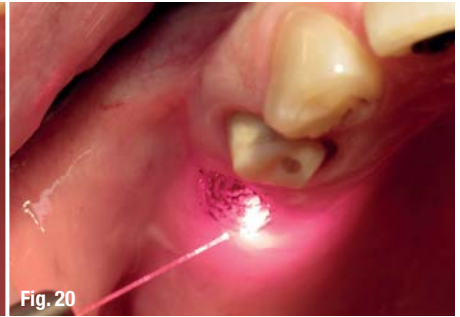

Fig. 20

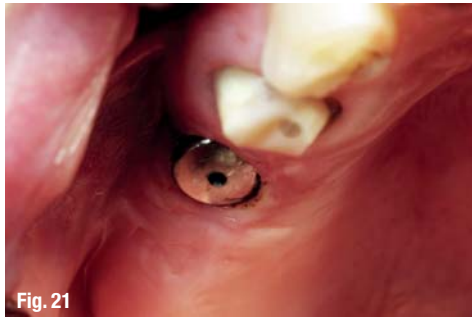

Fig. 21

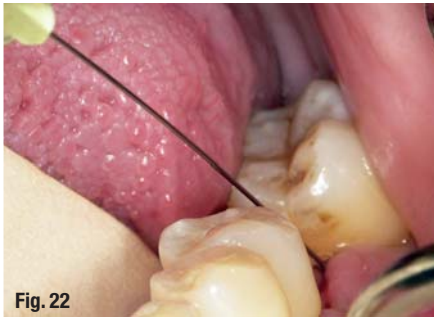

Fig. 22

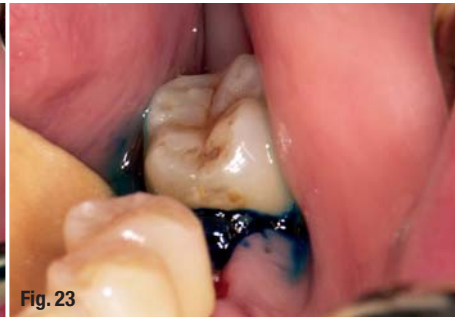

Fig. 23

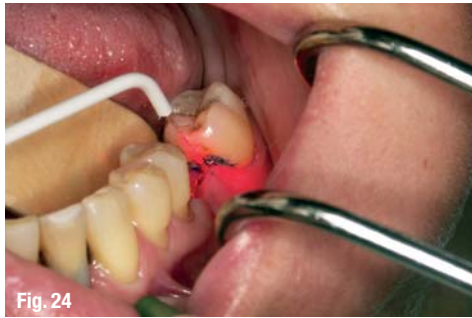

Fig. 24

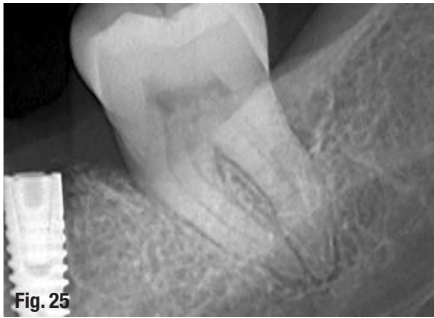


Fig. 25

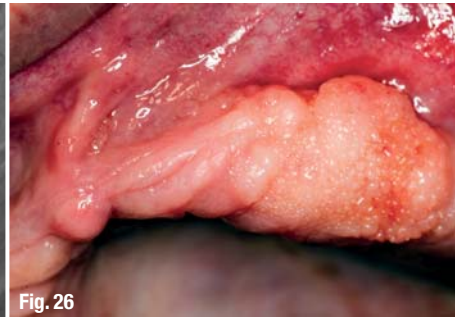

Fig. 26

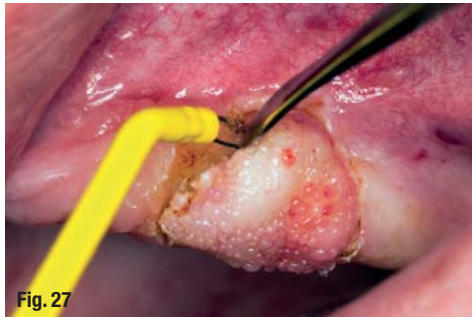

Fig. 27

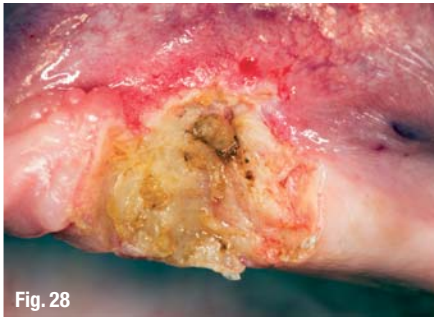

Fig. 28

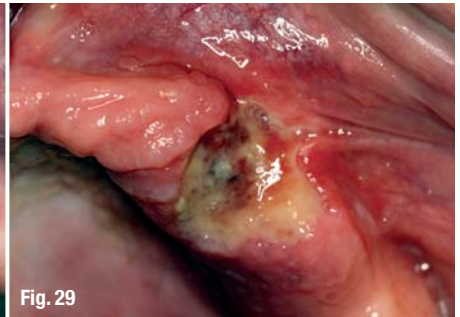

Fig. 29

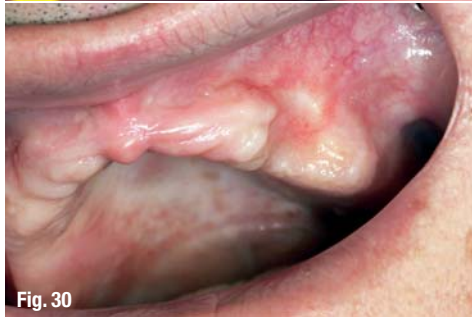

Fig. 30

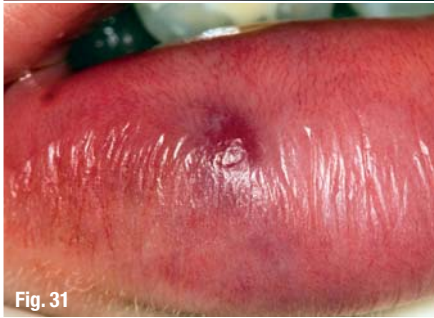

Fig. 31

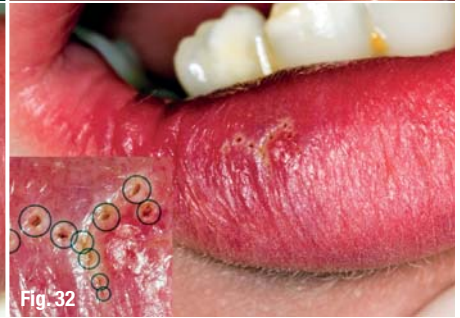

Fig. 32

**Fig. 18** Pre-surgical clinical view.

**Fig. 19** Re-contouring of the soft tissue using diode laser.

**Fig. 20** Application of aPDT before abutment fixation.

**Fig. 21** Immediate postsurgical view.

**Fig. 22** Application of photosensitiser gel through periodontal space and central ridge incision line.

**Fig. 23** Distribution of photosensitiser gel around the periimplantitis area.

**Fig. 24** aPDT, using red 660 nm diode laser.

**Fig. 25** Control radiograph, four weeks after finishing the treatment.

**Fig. 26** Presurgical clinical view.

**Fig. 27** Radiofrequency electrode cuts the carcinoma.

**Fig. 28** Immediate postsurgical view.

**Fig. 29** Follow-up after five days.

**Fig. 30** Follow-up, five weeks after surgery.

**Fig. 31** Pre-surgical view of hemangioma in the lower lip.

**Fig. 32** About ten single punctures with a thin needle electrode (see magnification).

is not only absorbed in the tissue and converted into heat, it also will be partially transmitted through the tissue and may cause unpredictable and undesired side effects in adjacent healthy areas. Furthermore, the cutting speed of a laser beam is limited by the fact that the tissue can only be removed in layers. Neither increasing the laser power nor using pulsed laser radiation can eliminate this problem.

### **A promising approach**

The combination of a diode laser and a modern radiofrequency generator in one unit is a useful and perfect tool for an extensive soft tissue management. The laser can treat the relatively thin and complicated oral tissue very selectively and shows promising and successful results in periodontics, endodontics and implant surgery. The radiofrequency technology on the other hand, because of its significantly higher cutting speed and perfect coagulation, has benefits in oral surgery. Tissue will be heated and cut simultaneously, homogeneously and very fast in the entire length of the inserted metal electrode. Damage to adjacent healthy areas are unlikely. If they do occur, they are predictable and can be planned. Photodynamic therapy (PDT), low level laser therapy (LLLT) and tooth bleaching make new, additional treatments possible. At the

Department of Oral Surgery at the University of Zagreb, Croatia, a clinical study was performed to demonstrate the use of the combined LaserHF® unit, consisting of a 975 nm diode laser with 8 W power (cw, pulsed), a 2.2 MHz radiofrequency generator with 50 W power (monopolar and bipolar) and a 660 nm diode laser with 100 mW power (cw), in various treatments of oral soft tissue lesions (Figs. 1 & 2). To all patients, local anaesthesia was administered before the procedures. Patients in this study showed significantly less oedema and hematoma as well as significantly less pain and higher satisfaction compared to conventionally treated patients ( $p < 0.05$ ).

### **Case presentation**

Out of these patients we present the following cases:

#### *Case 1*

A female patient aged 67 presented with palatal fibroepithelial polyp and inflammatory papillary hyperplasia of the hard palate (Fig. 3). The soft tissue surgery was performed with a radiofrequency loop electrode at 35 W and diode laser 975 nm with a power of 5 W in continuous mode (cw). Low level laser therapy (LLLT) at 660 nm followed for 90 s im-

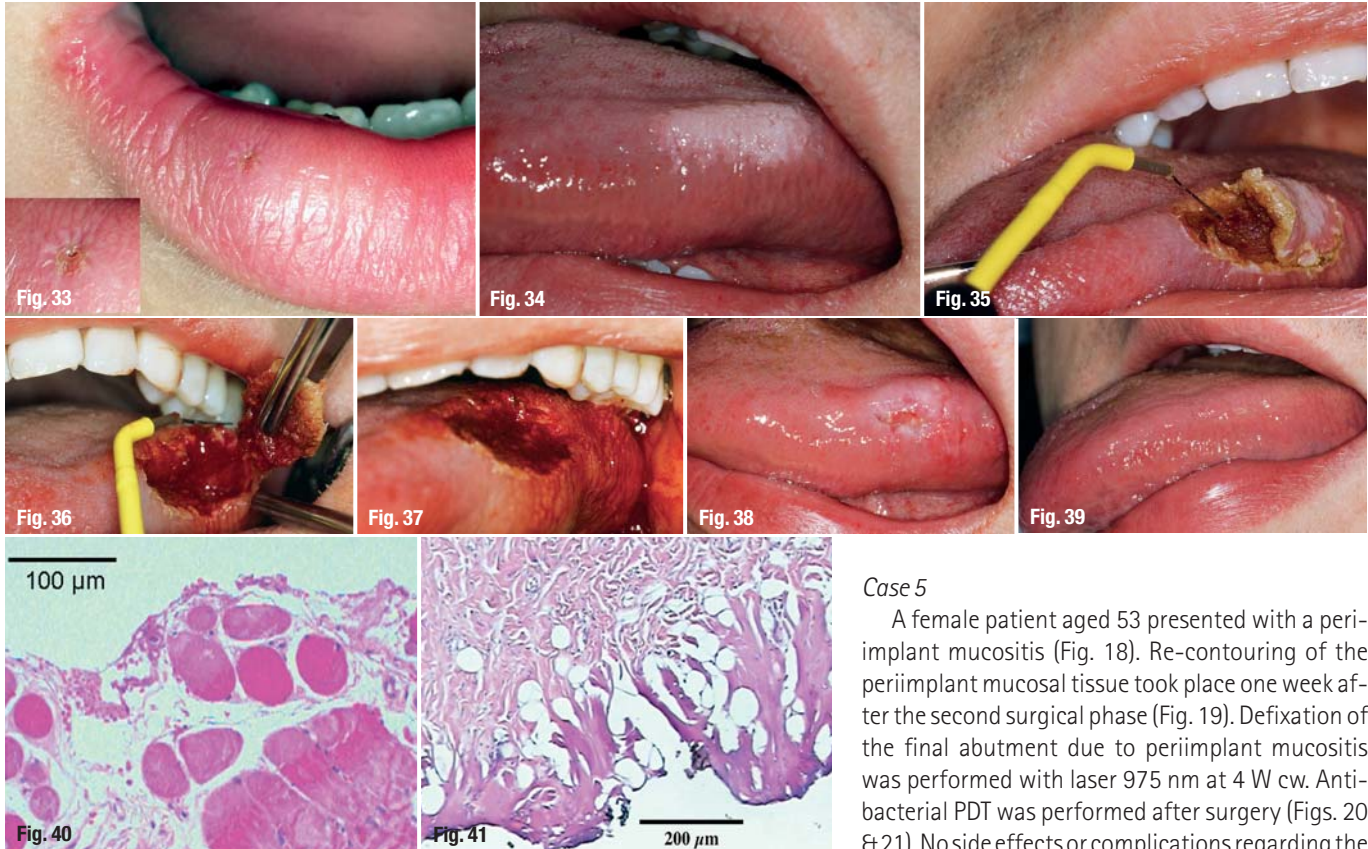
AD

*become an author  
for "laser"*

PICTURE: ©SHUKHVAI



Please contact Claudia Jahn  
✉ [c.jahn@oemus-media.de](mailto:c.jahn@oemus-media.de)



**Fig. 33** Following up after five days.

**Fig. 34** Leukoplakic, exophytic growing alteration (12 x 25 mm) at the left side of the tongue.

**Fig. 35** The tissue was very deeply removed from the tongue muscle to prevent any recurrences.

**Fig. 36** Due to the repeated growth and the unclear etiology, the tissue was deeply removed from the tongue muscle to prevent any recurrences.

**Fig. 37** This method allows an almost pressure-free work, resulting in straight-cut edges in the muscle.

**Fig. 38** Increasing epithelialisation two weeks postoperatively

**Fig. 39** An impressive macroscopic scar-free result eight months after surgery.

**Fig. 40** Alterations like thermal induced vacuoles in the striated muscle could not be seen after using radiofrequency technology.

**Fig. 41** Histological comparison of the thermal reaction zone produced with a 980 nm laser at 3 W cw. The broad and partially melted reaction zone is a result of a significant temperature effect

mediately after the surgical (Fig. 4) procedure was performed. Neither side effects nor complications occurred after surgery (Fig. 5).

**Case 2**

A female patient aged 23 presented with a mucocele in the lower lip (Fig. 6). The surgery was performed with the laser 975 nm at a power of 5 W in cw-mode (Figs. 7 & 8). The lesion was closed using a bipolar radiofrequency forceps (Fig. 9). LLLT application 660 nm with a power setting of 90 mW followed immediately for 90 s.

**Case 3**

A male patient presented with a giant cell granuloma of the upper jaw, central type in the frontal region of the maxilla (Fig. 10). The surgery was performed with radiofrequency cutting-mode (35 W) and laser 975 nm, 5 W cw. LLLT application followed immediately after surgical procedure (660 nm, 90 mW for a period of 90 s, Figs. 11 & 12). Follow-ups were taken two (Fig. 13) and five weeks after surgery (Fig. 14).

**Case 4**

A male patient, aged 82, presented with a metastasis of adenocarcinoma of the kidney (Fig. 15). Surgery was performed using radiofrequency cutting (35 W), coagulation grade 3 as well as laser 975 nm, 5 W cw, in combination (Figs. 16 & 17).

**Case 5**

A female patient aged 53 presented with a peri-implant mucositis (Fig. 18). Re-contouring of the peri-implant mucosal tissue took place one week after the second surgical phase (Fig. 19). Defixation of the final abutment due to peri-implant mucositis was performed with laser 975 nm at 4 W cw. Antibacterial PDT was performed after surgery (Figs. 20 & 21). No side effects or complications regarding the implant-bone interface after surgery were reported. Systemic antibiotic therapy was also included.

**Case 6**

A female patient with periimplantitis: Treatment of initial periimplantitis using closed technique was performed with systemic antibiotic therapy (Figs. 22 & 23) and aPDT (660 nm, 100 mW, 3 x 10 s) for ten consecutive days (Figs. 24 & 25).

**Case 7**

Male patient, aged 66, presented with verrucous carcinoma (Fig. 26). The surgery was performed with radiofrequency 35 W, coagulation grade 3—elliptic loop electrode and laser 975 nm, 5 W cw, in combination (Figs. 27–30).

**Case 8**

An 11-year-old girl presented with a haemangioma in the lower lip (Fig. 31). Low power radiofrequency application was conducted with 15 W, coagulation grade 2. A fine needle electrode (diameter 0.2 mm, length 5 mm) has been inserted into the tissue at about 10 points around the lesion, resulting in shrinkage of the tissue (Figs. 32 & 33). This treatment is not possible using the laser device.

**Case 9**

A 33-year-old patient presented with a leukoplakic, exophytic growing alteration (12 x 25 mm) at the left side of the tongue (Fig. 34). Considering the par-

ticular topography and anticipated depth of the lesion, the treatment was performed with radiofrequency at 2.2 MHz and a power of 50 W, using little coagulation (grade 1–2) simultaneously (Figs. 35–37). Monopolar operation was chosen with the neutral electrode on the shoulders of the patient. With a laser such a deep surgical operation would not be possible. After anaesthesia of the left N. lingual, the surgical area was marked with a fine, very thin electrode and the cutting line was defined in the range of the healthy mucosa. Follow-ups were taken two weeks (Fig. 38) and eight months (Fig. 39) after surgery.

The healing was without complications or serious swelling, but with moderate post-operative pain. There were no functional limitations, form and function of the tongue have been preserved or fully restored. The histological evaluation of the excised tissue showed no changes; only in the direct section area, a low thermal reaction zone was found (Figs. 40 & 41).

### Conclusion

For precise applications in dental soft tissues, especially surgical incisions, scalpel, laser and radiofrequency are appropriate tools. The right choice must be made by the dentist and is based on various criteria: If the lesions are relatively small and if they are more in the depth of the tissue, and no previous histopathologic evaluation is possible or useful, laser or radiofrequency are suitable devices. In contrast to the scalpel, a flushing out of abnormal cells and distant metastasis can be substantially averted. Besides, the scalpel always induces some mechanical stress to tissues which may lead to unprecise healing and thus cannot always claim a good cosmetic result. On the opposite, thermally produced incisions made by radiofrequency are fast and stress-free, providing excellent cosmetic results. They also deliver convincing results in more complicated procedures in the depth of the tissue. With appropriate coagulation, just minor tissue alterations are found, thus promising a good healing. The laser is more to be seen as a tool with strong importance in the treatment of superficial lesions due to its mode of layer-by-layer operation. Apart from treatments in periodontics, in endodontics, in PDT, Bleaching and LLLT, the laser is a perfect instrument for reshaping and smoothing of wound edges, for removal of overgrown implants, trimming of gingiva, drying and shrinking of tissue and of course even for small superficial surgery (Fig. 42).

Laser and radiofrequency technology show some delay in the epithelial regeneration. A wound

	LASER	Radio frequency	L + RF
Oral surgery	●	●	●
Periodontics	●	●	●
Implantology	●	●	●
Endodontics	●	●	●
Bleaching	●	●	●
PDT	●	●	●
LLLT	●	●	●

Fig. 42



Fig. 42\_ The laser is not perfect in oral surgery and the radiofrequency is not suitable in many other dental applications. However, in the combined device, they both can perform as perfect tools for the dental soft tissue management.

Fig. 43\_ The LaserHF® device.

takes some more time to re-epithelialise than following conventional surgery with a scalpel. However, they offer a minimally invasive technique with an intention to make surgical applications less extensive. They may reduce the need for general anaesthetics or hospital care, and therefore can lower the overall costs.

Considering the potential applications, the combination of a diode laser with a radiofrequency device meets the desire for a perfect system in the dental soft tissue management. The LaserHF® (by Hager & Werken, Germany, Fig. 43) is the worldwide first combination device. It consists of a 975 nm laser with a power of up to 8 W, combined with a 2.2 MHz radiofrequency generator—monopolar and bipolar—with a power of 50 W. An additional 660 nm laser with a power of 100 mW completes the device as therapy supplement for photodynamic (PDT) and low level laser therapy.

_contact	laser
<p><b>Hans-H. Koort</b>                  MedLas Consult                  Auf der Schleide 18                  53225 Bonn, Germany</p> <p>www.medlas.com</p>	

# Lasers in aesthetic dentistry

**Authors** Drs Ilay Maden, Zafer Kazak & Özge Erbil Maden, Turkey

**Figs. 1a & b** Crown lengthening before treatment (a).  
Crown lengthening 6 months after treatment (b).

**Figs. 2a & b** Gingival depigmentation before treatment (a).  
Gingival depigmentation 7 days after treatment (b).

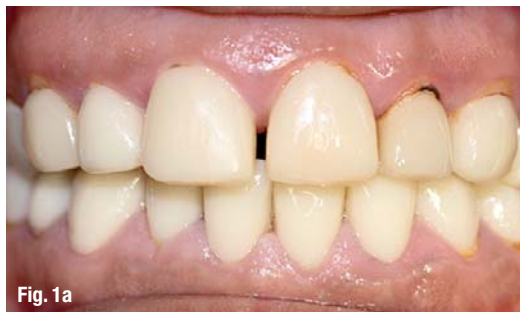

Fig. 1a

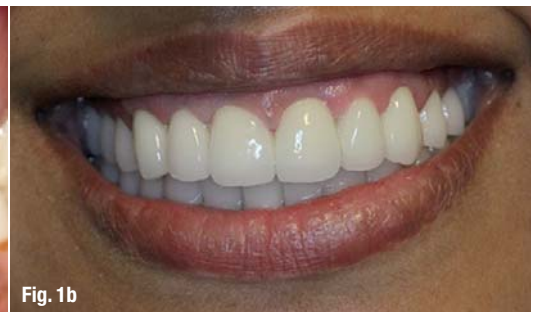

Fig. 1b

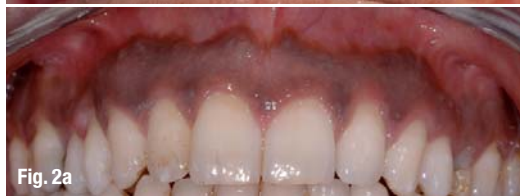

Fig. 2a

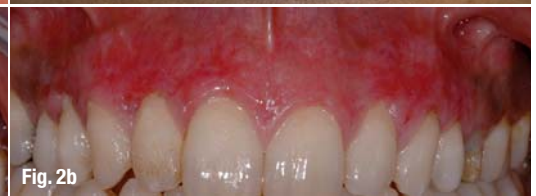

Fig. 2b

The exciting possibilities offered by the world of aesthetic dentistry are being experienced by an increasing number of dentists and patients worldwide as new materials, techniques and tools become widely available.

One such example is the laser, of which there are many for use in dentistry. To appreciate laser dentistry to its fullest, however, it is necessary to gain accurate information from unbiased sources, firstly about laser safety and the physics of laser-tissue interaction, and secondly about the specific uses of lasers in practice.

The most commonly used laser types in dentistry are erbium lasers (with two variants: 2,940 nm Er:YAG and 2,780 nm Er,Cr:YSGG), neodymium lasers (1,064 nm Nd:YAG) and diode lasers (810, 940 or 980 nm). Each type of laser has a different wavelength, and each wavelength has a different interaction with the specific body tissue being treated.

Crown lengthening or gingival levelling (Figs. 1a & b) is a routine procedure for laser-assisted aesthetic interventions. All lasers can be used for

this procedure; however, there are two main advantages of using erbium lasers in crown lengthening. First of all, they can be used without anaesthesia, as they do not cause thermal damage to the tissue. This results in a stable gingival height after the procedure.

Since diode and Nd:YAG lasers work in a more thermal manner, a longer healing time should be expected for the tissue to settle. A prerequisite for success in crown lengthening is, of course, to respect biologic width. If there is less than 3 mm between the desired gingival level and the bone, the bone level must be decreased. While this is possible to do with erbium lasers (even flapless), neither diode nor Nd:YAG lasers are suitable for this, since they are only capable of removing soft tissue.

The same conditions are applicable for uncovering implants with erbium lasers, so it is possible to take the impressions for prosthetic procedures on the same day or within a short period. If it is necessary to remove bone or soft tissue for either indication, erbium lasers with adjustable pulse duration (referred to as VSP technology in

Fotona lasers, for example) are the only option without raising a flap.


Tooth preparation for crowns and bridges with lasers is not yet as efficient as one might like it to be; however, new research and technological improvements are ongoing. A diode or Nd:YAG laser can still be helpful during prosthetic work for troughing before taking impressions or desensitising prepared teeth if required. It is also possible to reduce or eliminate dentine hypersensitivity due to periodontal treatment or gingival recession by either modulating the nerve endings or blocking the dentinal tubules using a laser.

Another aesthetic treatment is gingival depigmentation (Figs. 2a & b), which can also be performed by using long pulses of erbium or diode lasers. It is possible to de-epithelialise the surface, as the pigmentation is usually in the basal layer.

Erbium lasers are safer, since they do not penetrate the tissue. The effect is only superficial, and this is exactly where the pigmentation is.

Diode lasers penetrate more deeply, especially if one is not careful and tries to remove tissue that is lighter in colour. As with other treatments, erbium lasers allow the tissue to heal faster; however, there can be mild bleeding during the operation.

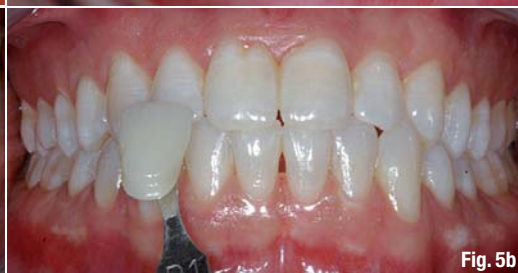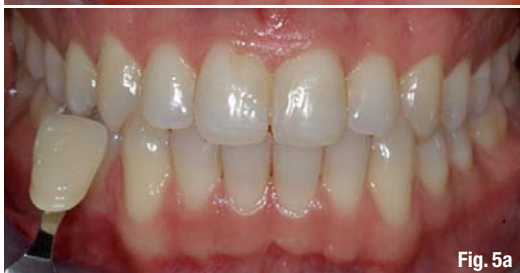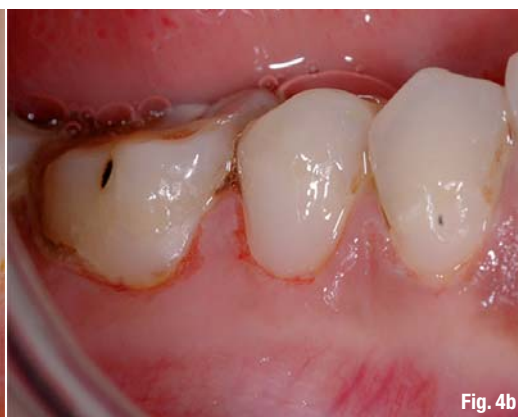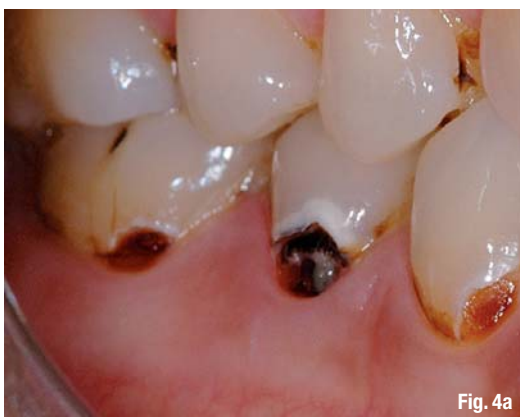Class V caries removal for composite fillings can easily be performed with an erbium laser, quickly, painlessly, and without any thermal side-



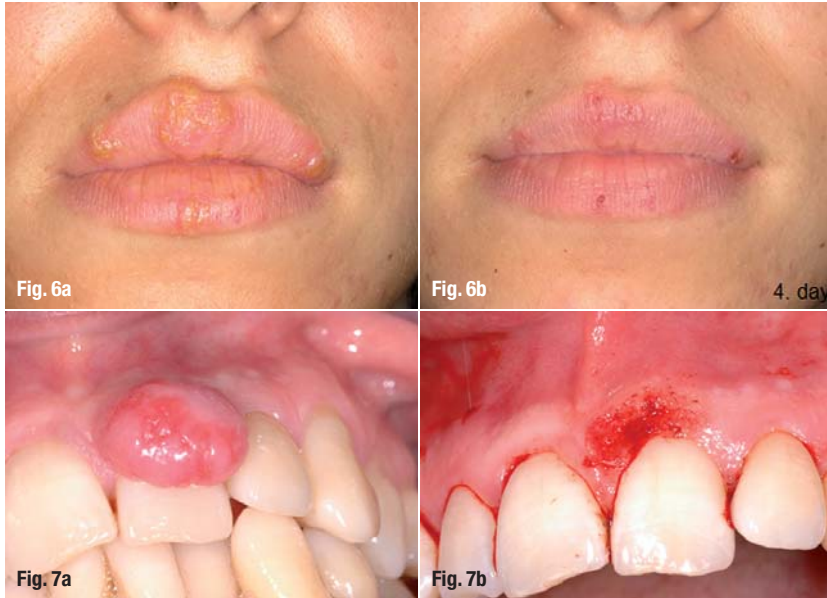
**Fig. 3**\_SEM image of hard dental tissue after ablation with an erbium laser.

effects, especially if the pulse durations are short enough—typically between 50 and 100 microseconds (Fig. 3). The shorter the pulse duration is, the more effective the laser energy will be at removing hard tissue. The margins of the cavity can even be bevelled for better aesthetic appearance and long-term colour stability if the laser is efficient enough to remove small amounts of sound enamel when needed.

Lasers also work selectively to only remove carious tissue, which has more water content than sound hard dental tissue. Surface modification can also be done with the erbium laser after cavity preparation for repairing composite fillings, or even for restoration cementation. One big advantage is that anaesthesia is not generally required when bloodless gingivectomy is used to uncover the borders of the carious lesion with an erbium laser using pulse durations of between 600 and 1,000 microseconds (Figs. 4a & b).



**Figs. 4a & b**\_Clinical case before treatment (a). Immediately after gingivectomy and carious lesion removal (b). **Figs. 5a & b**\_Before (a) and after TouchWhite procedure (b).



**Figs. 6a & b** Before (a) and four days after treatment of herpetic lesions (b).  
**Figs. 7a & b** Before removal of overgrown tissues (a) and immediately after the removal with an erbium laser (b).

For tooth whitening, lasers can also be used for activation of the bleaching gel (Figs. 5a & b), which decreases the treatment time as well as post-operative sensitivity. As the laser is absorbed by the appropriate gel, the heat is only superficial and the contact time is decreased, leading to less or no sensitivity.

The Er:YAG laser beam is uniquely absorbed in the water molecules that are contained in all gels. The more water content (the more the gel is "soft" and a bit runny), the better the resulting bleaching interaction (known as the TouchWhite™ procedure, patented by Fotona). The colour is not of importance for this interaction, unlike with Nd:YAG and diode lasers, which are absorbed more efficiently in pigments and therefore require specially coloured gels to be effective.

Nd:YAG and diode lasers have very specific indications, such as the treatment of herpetic lesions (Figs. 6a & b) and non-invasive haemangioma, which can present aesthetic problems too. The advantages of treating a herpetic lesion by laser are that the pain is relieved shortly after lasing, the lesion heals faster and reoccurrence is less frequent in the treated area.

For haemangioma treatment, the lesion is coagulated by the strong absorption of the laser energy in haemoglobin, after which it is either left to be removed by mast cells or ablated.

The bio-modulation effect of these lasers is also advantageous, helping to increase cell turnover and blood circulation (with an anti-inflammatory effect), eliminate pain, improve nerve transmission, promote myo-relaxation, stimulate

the release of growth hormones, and improve many more aspects of healing.

Other procedures like frenectomy or removal of overgrown tissue (lasers can be used to safely and easily remove tissues, like overgrowth, pigmentation, etc. but it is essential to be certain about the nature of the tissue that is being removed) can be carried out for aesthetic reasons in the anterior region (Figs. 7a & b).

Erbium lasers are preferred for soft-tissue surgeries like these because they are fast, require minimum anaesthesia and do not cause a delay in healing. It is important, however, to be able to modify the parameters: if the pulse duration can be increased above 600 microseconds, preferably up to 1,000 microseconds, the quantity of heat delivered will rise—still without damaging the tissue—and cause haemostasis. If this cannot be achieved with the particular Er:YAG laser system, then a second wavelength must also be employed, such as diode or Nd:YAG in order to effect haemostasis.

Diode and Nd:YAG lasers can be used from start to finish for all soft-tissue interventions to yield blood-free surgery; however, this requires more anaesthesia and a longer healing time.

All of these benefits and many more increase the comfort of the patient and give dentists more reasons to enjoy their profession. For achieving a full and successful integration of laser technology into a clinician's treatment offering, and to make effective use of the investment made, as well as to ensure the health and safety of patients, it is necessary to obtain an adequate education in both the biophysical interactions underlying these treatment protocols and the specific properties of each laser device.

*All procedures presented in this article were performed using a LightWalker AT dental laser system (Fotona).*

<b>_contact</b>	<b>laser</b>
<p><b>Dr İlay Maden PhD, MSc, BDS</b>                  Mühürdar Caddesi 69                  34710 Istanbul                  Turkey</p> <p>ilaymaden@gmail.com</p>	




The logo for ADA 2014 features a stylized 'A' composed of three curved segments in red, green, and blue, followed by the text 'ADA.2014' in a bold, sans-serif font.

AMERICA'S DENTAL MEETING

October 9-14, 2014 | San Antonio, Texas, USA

**Education:** October 9-12 | **Exhibition:** October 9-11



### Education

Participate in challenging CE courses that fit into your schedule and budget



### Exhibition

Research and purchase dental products and services at a discount



### Connections

Mingle with colleagues from across the world

# Gain power at your laser clinics!

Author\_Dr Anna Maria Yiannikos, Germany/Cyprus

## Introduction

During this issue we are going to explore the first element of marketing mix which is the package in our case the service that we deliver in our offices. Dental treatment is an intangible service therefore a very important role is played by the quality.

Do you know how quality is perceived in the mind of our patients? First by the past experiences our patients have had from us or from other colleagues. Second from the word of mouth, which is our most powerful marketing tool, what others are saying about us and finally, from the personal needs that our patients have. As an example we can start with their need of experiencing minimal pain during a treatment. Many get afraid or annoyed by the sound of the drill; in this case they will prefer to choose a laser dentist. The above are factors that we have to meet during the services that we offer. We should understand that we do not only deliver services but a culture; the culture and mentality of our clinic through the experience that our patients re-

ceive. They do not only expect from us to be just good doctors. If we think like this we are wrong! They expect from us to be the best, period. Our patients will not just compare us with other dentists but with all the service experiences that they have like as in a hotel or in a restaurant.

Our competitors are everyone when it comes to our patients; the manager in a restaurant, the receptionist in a hotel. Our patients hold in mind a mental picture of how they think they should be treated and this picture becomes their standard by which their experiences are judged.

## Law of memorable event: determines dissatisfaction and loyalty

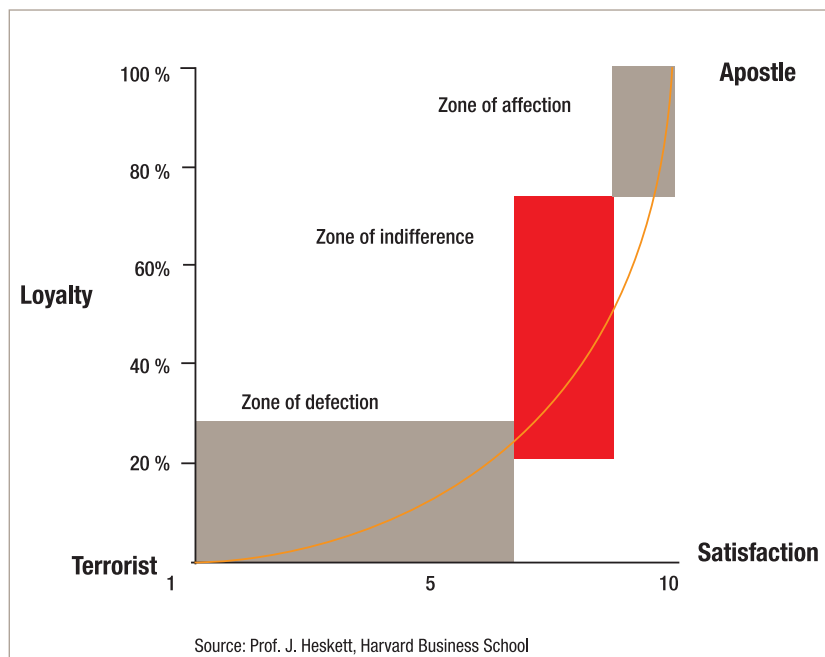
When nothing makes either a good or a bad impression on you, your feelings are neutral. It takes something memorable to turn ordinary satisfactory experience into something special. Dissatisfaction comes from something bad that you experienced and you remember. Furthermore, loyalty is generated by memorable things that happen, that we weren't expecting. And if our patients do not remember us, why should they choose to continue to come to us?

As we can see from Figure 1, we have three zones when we interrelate satisfaction and loyalty:

1. The zone of defection, which includes the terrorists—all the dissatisfied patients that discourage others from visiting us. This zone gets narrower as the relationship between dentist and patient matures and goodwill is added in the emotional bank account.
2. The zone of indifference, where the patients are satisfied but they might visit other colleagues as well for their treatment or they will not refer us to others.
3. Finally the zone of affection containing the apostles—the very satisfied patients, the loyal patients that talk favourably about our services and their experiences and they will spread through the word of mouth how thrilled they are with us, encouraging friends and relatives coming to us for their dental treatments.

Fig. 1 Relation between satisfaction and loyalty.

Source: Professor J. Heskett, Harvard Business School.



A question that might arise is: how can we minimize the zone of defection?

Exit interviews or measuring regularly our patient's satisfaction with surveys can have an extreme impact on our profits since through them we can learn in which areas we lack in so to improve.

And here comes another question to consider: How many of us administrate patient satisfaction surveys, how often and when do we imply them? As mentioned before, dental treatment is an intangible service (= we cannot measure it like a product). Therefore, the quality plays a very important role.

How do patients measure the quality of our practice?

Patients cannot judge how well we can fill a root canal or how nicely we polish a composite filling—in- stead, quality is effectively perceived from our patients by the below factors:

1. Appearance: the way our office and our staff look.
2. Security of our clinic: In which way do we increase our patient's confidence that they belong in a safe place and can relax and trust us for the best? Some examples are the existence of safety signs and flash lamps outside the doors, laser safety diploma, safety glasses that we provided to them during laser treatments, accreditations we have gained like ISO 9001 (for quality) or OSHAS 18000 (for health and safety). These are just some of the options that we have that constantly remind our patients of our best interest in the quality.
3. Reliability: Our ability to keep a consistent level of a laser treatment. Is our treatment plan performed as told from the beginning? If we promise our patients that they will have a painless treatment, will this we be able to keep our word? Our patients must know the truth from the beginning. No promises must be given that cannot be kept in order for our patient to trust and rely on us.
4. Responsiveness: Do we respond quickly to their problems? Or their phone calls? Are our staff members willing to answer their questions with care and seriousness expressing simultaneously their knowledge and skills?
5. Competence: Our patients ought to understand that we are not only skillful and that we do not only have the equipment but we also possess the knowledge to provide laser treatments.
6. Courtesy: We have to be polite not only with our patients, but also show our friendliness towards our employees as well: "Treat your employees as your patients and your patients as employees".
7. Credibility: We ought to be honest and have a good reputation
8. Access: People value nice people since this makes them happy. We cannot describe to them how nice we or our staff is, they have to see for themselves—we have to walk the walk through internal and external acts of niceness. We should be approachable and ease to

contact. If, for example, we have a secretary that is at all time distracted and cannot be reached from our patients, this will create a bad impression for our entire clinic.

9. Communication: We must know what, when and how to say something. We must master verbal, non verbal communication skills so as to show them that we understand them with sympathy and compassion; understand not only their needs, but also their fears.

Let's look at the following example: If we are explaining the treatment to Mr Smith like this: "Mr Smith, today we are going to make a cavity preparation using VSP, 20 Hz with water and air using our Er:Yag laser. Are you ok with that?" What do you believe that we are going to achieve through this? Loose him instantly as a listener!

Let's close the referral to the first element of marketing mix by remembering the Gucci family motto: "Quality is remembered long after the price is forgotten". In the next issue, we are going to talk about the second element of marketing mix, which is the PRICE.

A fruit for thought: Let's not forget who our patients are. All of the people that we meet daily, the receptionist at a hotel, the bank cashier, our hairdresser, all the people that we come into contact with can spread the word of how wonderful or miserable we are... In which of the two groups do you want to belong to? I leave this decision up to you.

Last as a closure allow me to proudly announce the launch of DBA mastership course in Europe under the umbrella of AALZ—RWTH Aachen University Campus. A mini MBA designed only for dentists scheduled to begin on the 1<sup>st</sup> of May 2014. It is a course for the dentists that want to gain their power back! For those that have the desire to master the skills of management and administration for their own clinics, where many of the above and many more matters will be taught in more detail. Looking forward to your questions and requests for further information at: [dba@yiannikosdental.com](mailto:dba@yiannikosdental.com)

[\\_contact](#)

[laser](#)



**Dr Anna Maria Yiannikos**

Adjunct Faculty Member of AALZ at RWTH Aachen University Campus, Germany  
DDS, LSO, MSc, MBA

[dba@yiannikosdental.com](mailto:dba@yiannikosdental.com)  
[www.yiannikosdental.com](http://www.yiannikosdental.com)



# The right to be pain free

**Author\_** Dr Michael Sultan, UK

**Pain is defined by** the World Health Organization (WHO) as "an unpleasant sensory or emotional experience associated with actual or potential tissue damage, or described in terms of such damage."

While recognising its existence, what the WHO doesn't mention is that pain is, of course, entirely subjective, which is one of the reasons that it is such a challenge and a major global public health issue. We probably know far more about pain and its treatment than ever before, yet there is a disconnect between having that knowledge and using it to treat and manage pain.

I believe passionately that dental professionals in general, and endodontists in particular, should commit to the right of every patient to be free of pain and, through our work as compassionate professionals, to understanding acute pain management, if we are to provide real health and emotional benefits for our patients.

During the 2010-11 "Global Year Against Acute Pain", the International Association for the Study of Pain published a paper that points to inadequate education of health-care practitioners as one of the

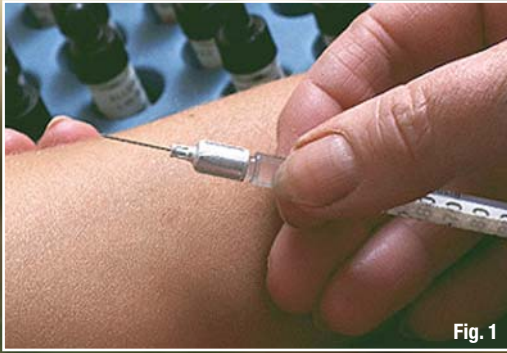


Fig. 1



Fig. 2

different pain thresholds and, indeed, vastly different capacity to deal with it. Interestingly, the Australian and New Zealand College of Anaesthetists puts at the very top of its list in a statement on Patients' Rights to Pain Management: "The right to be believed, recognising that pain is a personal experience and that there is a great variability among people in their response to different situations causing pain."

Acute pain is the awareness of noxious signals from damaged tissue and is complicated not only by sensitisation in the periphery but also by changes in the central nervous system. A person's emotional state can often have a significant influence on pain and increase the level of distress and impact on quality of life. Pain is hugely debilitating and makes life extremely miserable for millions of people every day, and there are many underlying cultural, economic and social reasons that should also be taken into consideration.

I firmly believe that the dental profession must work with the government, policymakers and campaigners to ensure that every patient has access to pain-free dentistry. In some cases, this will mean that NHS patients will receive treatment from private dental specialists, an issue raised by the Steele report, which suggests that poorer patients are forced to settle for extractions and dentures rather than tooth preservation, with root-canal treatments the preserve of the rich.

While there is no legally enshrined right to be pain free, there are those who believe that the internationally established and recognised rights to health include that by implication and inference. We can at least encourage greater awareness, better education and knowledge sharing, as well as raising patient expectations to be pain free.

**Fig. 1** By understanding the use of anaesthetics and analgesics, dental staff are better placed to offer information and help to their patients.

**Fig. 2** Every patient has the right to be pain free.

main reasons for underestimating the seriousness of, and failing to recognise treatment options for, acute pain.

It is clear therefore that, despite huge advances in a vast array of sophisticated medical and non-clinical treatment options, we are part of the problem so we must become part of the solution.

By increasing our own awareness and understanding of the issues surrounding the assessment and treatment of acute pain, we can, in turn, help educate our colleagues in the use of anaesthetics and analgesics so they are better placed to offer information and help to their patients, many of whom are reluctant to use painkillers for fear of unpleasant side-effects or even, addiction.

Pain is both physical and emotional, which is the reason that it is fundamentally important to recognise that it is subjective and that different people will have



laser



**Dr Michael Sultan** (BDS, MSc, DFO, FICD) is a specialist in endodontics and the Clinical Director of EndoCare, a group of specialist practices. Michael qualified at University of Bristol in 1986. He worked as a general dental practitioner for five years before commencing specialist studies at Guy's Hospital, London. He completed his MSc in Endodontics in 1993 and worked as an in-house endodontist in various practices before setting up in Harley St., London, in 2000. He was admitted to the specialist register in endodontics in 1999 and has lectured extensively to postgraduate dental groups, as well as presented endodontic courses at the Eastman Dental Institute's CPD department, University of London. He has been involved in numerous dental groups and has been chairperson of the Alpha Omega International Dental Fraternity. In 2008, he became clinical director of EndoCare.

# Manufacturer News

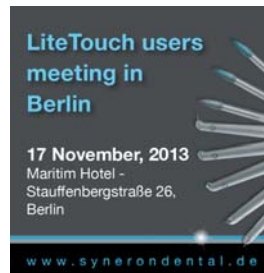Syneron Dental Lasers

## LiteTouch™ Users Meeting & Clinical Training in Germany

LiteTouch™ 2013 Users Meeting & Clinical Training will take place during November 17 at Maritim hotel in Berlin, right after the 22<sup>nd</sup> Annual Congress of DGL. Limited seats are still available at [www.synerondental.de](http://www.synerondental.de). The event will include laser dentistry clinical training and R.O.I. management by international renowned KOL as well as a Laser dentistry brainstorming and experience sharing. The 2013 LiteTouch™ Users Meeting is a unique opportunity to experience and feel the Syneron Dental Laser Family exclusive environment. Syneron Dental Lasers is a leading international company providing dental laser technology for both hard & soft tissue dental treatments. The company achieved significant global market share and transformed the way practitioners perform dental treatments today, with its Laser-in-the-Handpiece™ innovation, the first

all-tissue, non-fiber, non-articulated arm Er:YAG dental laser equipment.

The LiteTouch system allows dentists to focus on their performance of the clinical treatment and on their patients, rather than being constantly concerned about causing damage to the laser fiber. Thus, dentists can quickly and easily integrate LiteTouch™ into their daily routines and enjoy the complete expression of their dental mastery. LiteTouch™ is used in a variety of dental treatments such as cavities & restorations, pocket debridement, calculus removal, apicoectomy, implant site preparations, peri-implantitis treatment, gingival recontouring & children's

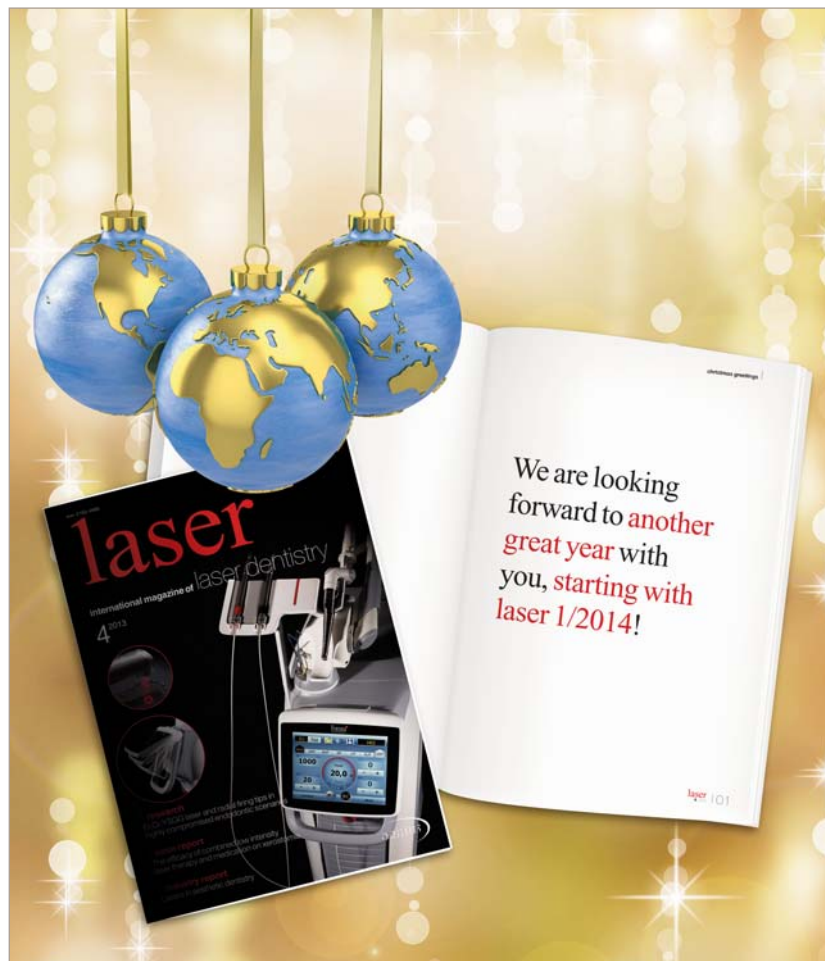

pits and fissures among other treatments. Syneron Dental Lasers was recognized and distinguished with four international awards, Red Dot Design Award (2013), A' Design Award (2013), Best in Bizz Awards 2013 EMEA, Deloitte's 2011 EMEA Technology Fast 500.

**Syneron Dental Lasers**  
Tavor Building, Industrial Zone  
20692 Yokneam Illit, Israel

Deutschland@syneron.com  
[www.synerondental.de](http://www.synerondental.de)

AD



BIOLASE

## 15<sup>th</sup> Anniversary of Waterlase

As the world leader in dental lasers, BIOLASE has created a strong technology lineup starting with the most advanced all-tissue laser, WaterLase iPlus. Beginning October 2013, BIOLASE is celebrating the 15<sup>th</sup> Anniversary of WaterLase. This laser has helped practices achieve both clinical excellence and patient satisfaction. WaterLase iPlus eliminates the need for anesthetic, allows for multi-quadrant dentistry in a single visit, and can expand your ROI. The iPlus helps to eliminate microfractures associated with the traditional drill, as well as thermal damage and cross-contamination risks. Also from BIOALSE is the EPIC diode which has three unique modes—soft tissue surgery, whitening and pain therapy. It has the power, portability, and high performance for greater patient comfort. iLase is the first personal diode laser. With no foot pedal, power cord or external controls, this laser was designed to be affordable.

**Biolase Europe GmbH**  
Paintweg 10a  
92685 Floss, Germany

Tel.: +49 9603 8080  
Fax: +49 9603 2360

[info@biolase-europe.com](mailto:info@biolase-europe.com)  
[www.biolase.com](http://www.biolase.com)



# CROIXTURE

PROFESSIONAL MEDICAL COUTURE



EXPERIENCE OUR ENTIRE COLLECTION ONLINE

[WWW.CROIXTURE.COM](http://WWW.CROIXTURE.COM)

# Biolase could become the next Intuitive Surgical

Source\_Biolase

In a recent statement, US-based provider of dental and medical lasers BIOLASE announced that health care fund Camber Capital Management in Boston in the USA has purchased US\$5 million of the company's common stock. Dental Tribune ONLINE had the opportunity to speak with CEO Federico Pignatelli about what this means for the company, mistakes of the past and the reasons that the company's WaterLase technology has the potential to revolutionise dental surgery.



Federico Pignatelli, CEO BIOLASE

**DENTAL TRIBUNE:** *Mr Pignatelli, your company seems to have been struggling recently, according to some analysts. What is your company's position right now, and what does the recent sale of shares to Camber Capital mean for your business?*

The confusion arises from the fact that we grew 40 to 50 per cent a year for two years and in 2013 our growth has slowed down to "only" 15 to 20 per cent. We believe that BIOLASE will grow strongly in the years to come. We just needed to raise our capital with a few million dollars in order to improve our balance sheet. This capital raise, combined with our US\$8 million Comerica Bank credit line, will give us enough capital to continue our plan of business expansion.

Also, as we approach the fourth quarter we see net income and positive cash flow returning and we are expecting this positive development to continue in 2014. So we feel very positively about where BIOLASE is right now.

*So have the recent restructuring measures paid off?*

Yes, they have paid off handsomely, but there is more to do. I admit that in the past there have been some unhappy customers, but in our defence the company back then was managed by entirely different people and was locked into an exclusive global distribution agreement with Henry Schein. In the new BIOLASE, customers are the number one priority and we do what it takes to take care of them.

What people need to realise is that BIOLASE is a cutting-edge technology company with a new technology that is potentially going to radically transform the way dental surgery is performed and practised.



As a new step in informing the marketplace about WaterLase, we have recently embarked on a social media and press campaign to reach out to millions of patients to educate them about the many advantages of being treated with BIOLASE's technology.

We are particularly glad to have Dr Fred Moll, the co-founder of Intuitive Surgical, who values our technology such that he joined our board of directors recently. He is a legend in the medical field because with his company he transformed the way surgery is approached through the use of robotics. Thanks to a visionary like him, today tens of thousands of patients with cancer can be treated in a much more precise way than ever before.

We believe BIOLASE has a technology that is so advanced and revolutionary that the company could become the next Intuitive Surgical. That is because with WaterLase technology we can transform surgical dentistry for hundreds of thousands of dental practices around the world, while providing better and safer care for patients.

*Why do you think lasers and particularly WaterLase will be the technology of choice in dentistry for the future?*

If you think about it, dentistry has not really changed very much since the dental drill was invented by the Egyptians 7,000 years ago. The principle of removing tissue by mechanical rotation has remained the same since that time, with the only major change in the past 70 years being the attachment of a high-speed engine. With WaterLase technology, we are able to make use of the most basic element of human tissue, water. The human body in its entirety consists of 60 per cent water, so water can be found in almost all tissue. Dentine, for example, has 20 per cent water in it. By energising water molecules with a laser, tissue can be cut without pain, heat, abrasion, vibration, or the risk of microfractures. At the same time, it is also much more precise. Clinically, this is much better dentistry.

Furthermore, there is no need for any anaesthetic for the patient; 99 per cent of patients can be treated without using Novocaine. How wonderful is that? On top of that, laser energy kills bacteria, viruses and fungus, and that provides another advantage for dentists, since it is almost impossible and certainly very costly to have surgical instrumentation like dental burs and endodontic files fully sterilised, and too costly to use new instrumentation for every patient to be treated.

*With all these advantages, why does it seem that the technology has not been adopted widely by dentists yet?*

That is not exactly true. Since the introduction of WaterLase technology 15 years ago, we have sold over

10,000 units worldwide, 6,000 of which were in the USA alone. The main challenge however is education. Dentists need to be better educated about the return on investment and the system's extensive clinical advantages in comparison with conventional dentistry.

In fact, only two and a half years ago, WaterLase technology for the very first time broke the speed barrier, which means that it now cuts as fast as a conventional dental drill, sometimes even faster. Furthermore, it allows impressive treatment and cutting of soft tissue, which is something a dental drill cannot do. These additional options mean that dentists no longer need to refer patients to a specialist for these tasks, thereby boosting revenue in the practice.

*Where do you see the technology in the next five to ten years?*

In contrast with other market-leading systems or technologies, such as Sirona's CEREC, WaterLase is protected by over 100 patents, which will allow us to protect our competitive advantage. The adoption cycle of new technologies is growing increasingly shorter and more advanced technologies like WaterLase will rapidly find their way into dental practices. Dentists that do not upgrade their practices will likely begin to lose patients, become uncompetitive and lag behind. You cannot fight technology; you cannot fight innovation. If you do, you are doomed to be left out of the market.

We regularly ask patients whether they would like to be treated by a conventional dentist or high-tech dentist, and almost 100 per cent of patients would like to be treated by a high-tech dentist. Therefore, we believe that WaterLase will be part of most dental practices in the near future.

*Thank you very much for the interview.*

*Editorial note: Dental Tribune is the international cooperation partner of **laser international magazine of laser dentistry**.*

**\_contact**

**laser**

**Biolase Europe GmbH**

Paintweg 10  
92685 Floss  
Germany

Tel.: +49 9603 8080  
Fax: +49 9603 2360

info@biolase-europe.com  
www.biolase.de

# Dentures produced using 3-D printing versus casting and milling

Non-precious metal alloys (NEM) are enjoying increased demand in dental technology. Additive manufacturing with laser melting ensures the uniformity and accuracy of ceramic-veneered, non-precious metal restorations created from dust and light. Are the traditional manufacturing processes of dental technicians, such as casting and milling, making a comeback? We spoke with Master Dental Technician Dieter Spitzer of Unicim, a manufacturer of dental restorations based in Berschis in the Swiss canton of St. Gallen.



**Fig. 1** Tailor-made dental technologies: Master Dental Technician Dieter Spitzer offers traditional manufacturing along with CAD/CAM methods, such as laser melting of metals for dental restorations.

All images courtesy of Concept Laser GmbH, Lichtenfels, Germany.

*Mr. Spitzer, you refer to Unicim as a digital production center. What do you mean by that?*

Unicim combines traditional production methods with digital CAD/CAM manufacturing, such as metal laser melting or powder-based plastic laser sintering. With rapid manufacturing methods, you can select the most functional and affordable dental prosthetic solution based on your customer's needs, be it crowns and bridges, frameworks, primary and secondary structures or implant supra-constructions.

*Can you give us an idea of the process for creating dental restorations out of metal by using the additive manufacturing technology?*

Once the 3-D CAD data is complete, the support structures are set up with the help of a data processing software. Various software solutions are available for this purpose. One of the most common is CAMbridge, which requires license fees.

Alternatively, there is AutoFab Mlab, which is license-free and allows you to assign specific measurements. With Concept Laser systems, the customer is able to choose freely and is not bound by any software. The processed data is then transmitted to the machine via the network or USB port and the construction job is started. With this process, you can finish a project fully automatically overnight. Once complete, the components are removed from the building board and refinished. After manually removing the support structures, the surface is then microblasted with aluminum oxide and, in the case of bridges, the crown edges are thinned down.

*Will milling and casting soon be a thing of the past in dental prosthetics?*

Milling and casting will remain part of the standard repertoire of dental laboratories for training and application. Additive manufacturing options

will offer many advantages in the future and reduce production risk enormously. Unfortunately they are still far too rarely seen in practice by dentists and dental technicians. Some of this has to do with the old school mentality of doing everything manually. The dental laboratory of the future will be more of a hybrid: milling and casting where desirable but with additive manufacturing as a top alternative. "Add on versus take away," I like to call it. In summary, the casting process, from creating the cast object to the finished product, is usually very time consuming and can lead to distortion, especially with large-span restorations. With additive technology, we achieve contour accuracy more easily than with milling. Our workplaces in dental technology are also cleaner thanks to CAD/CAM: less dust, less bonding agent, glue and outgassing. Ultimately, the deciding factor is quality. Compared to casting and milling, additive printing processes are creating entirely new ways of thinking in terms of production, workflow and the products themselves.

*How are these changes expressed?*

We need to look at different levels here. First is the transition from manual craftsmanship to high-precision, high-accuracy industrial CAD/CAM production. Milled non-precious metal restorations have significant disadvantages due to material consumption: high production costs and system-related lower quality in terms of fit and shape retention. During casting, we also encounter disadvantages in terms of low material density, mold costs, production time and rework. Nearly all of these disadvantages disappear with laser melting. By using proven materials like remanium star CL and rematitan CL from Dentaureum with our Mlab cusing R, we have been very satisfied with the quality of our system-manufactured products. In the case of large-volume restorations, any excess tension that arises can be alleviated through subsequent heat treatment, thus avoiding any potential distortion. Of course, the same applies to cobalt-chromium alloys or titanium.

*You mentioned changes in the products. What changes were you referring to?*

I'm quite optimistic. I'll describe a couple of them. First, the geometric flexibility of prosthetics is enabling a new way of looking at shapes or functions. In the future, imagine restorations with channels into which medications can be fed. The dentist or orthodontist can provide treatment, and the patient won't have to deal with temporaries. The second major change is the selective density of a component made possible by the process. Thus, for example, bridges with more than

ten sections can not only be manufactured in a one-step process tension-free, they can also be increasingly applied in heavily utilized areas, such as cantilevers, edges or brace elastics. In model casting, that's not always an easy problem to solve. Geometric freedom is a genuine plus for us, as it opens up new possibilities for restoration design. For example, brace elements can be made much finer while retaining sufficient mechanical properties.

These new options also increase the longevity of dental product. In casting or milling, we have to deal with cost, material waste and lower material density; in casting especially, we have oversized dimensions and much lower material densities. With cast restorations, breakage is always an issue. But it doesn't have to be that way. Another benefit is the ability to create combinations through module or multicomponent construction methods. Base elements implanted into the jawbone are used as primary structures. An additively manufactured foundation element is then put into place as a secondary structure, onto which a secure, durable veneer such as HeraCeram is applied. Another aspect relates to new materials, such as non-precious metal titanium...

*Titanium would be hard and biocompatible...*

Titanium is the ideal material for allergy sufferers, for example. In combination with laser melting and veneering, we can maximize its biological benefits. From a visual standpoint, titanium restorations offer a risk-free silver-gray luster. Manufacturers of non-precious metal alloys have spread pseudoscientific criticism regarding its aesthetics.

Low-dose fluoride in toothpaste or mouthwash, for example, has no impact on appearance. We can't deny the reality that titanium has not only caught up to non-precious metal alloys in importance, it has surpassed them. This is precisely why, in 2012, Unicim invested in a Mlab cusing R system for titanium applications from Concept Laser, which allows us to process reactive titanium material in a closed system. The unit can be used with dental materials certified under the German Medical Devices Act, such as rematitan CL from Dentaureum. Because of the high amount of material waste, milling-based processing of titanium is too expensive and casting is highly impractical.

*What are some of the problems that arise in the casting of titanium?*

The reaction of titanium with oxygen causes a so-called alpha-case layer to form on the outside. This leads to embrittlement of the surface and



Fig. 2

LaserCUSING®  
Quelle: Concept Laser GmbH

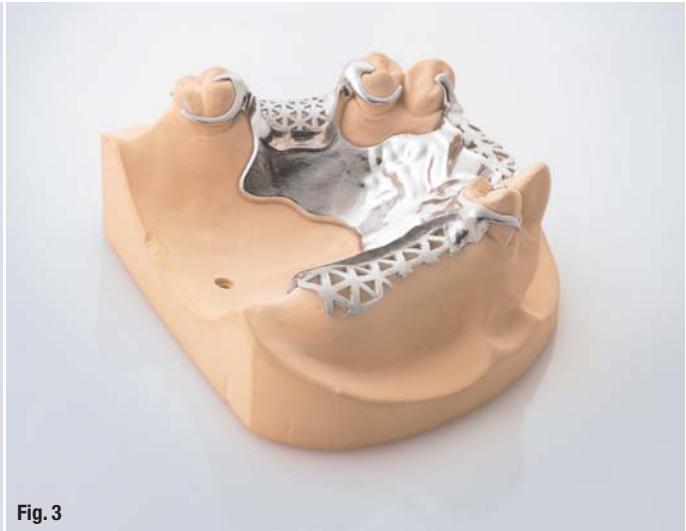

Fig. 3

**Fig. 2** Crowns and bridges manufactured using laser melting technology.

**Fig. 3** Cast parts manufactured with LaserCUSING.

must be removed. If not removed, it can lead to problems with the adhesion of veneering. With LaserCUSING, no alpha-case layer forms. This makes laser melting with titanium powder excellent for processing. The very fine-grained microstructure of the laser-fused parts of this titanium alloy allows greater firmness than with conventional castings. The dentist receives a high-performance, long-life alternative that's easy to work on and more affordable than a precious metal solution. Finally, dentists and patients can benefit from a quality product that is both durable and natural in appearance.

How does titanium compare in terms of price?

The price of the Dentaurum titanium powder we use is currently around 595 euros per kilogram; a 4-unit bridge weighing 4 grams thus costs EUR 2.40 in materials alone.

Why has laser melting been so slow to catch on in the dental industry?

The reasons for this are many. The process is relatively new, so the learning curve is enormous. The fact that the quality of laser-fused products is better than conventionally manufactured dental restorations remains largely unknown. Its reputation continues to be tarnished by ignorance or misconceptions. Keep in mind, too, that dental technician training takes four years in Switzerland, and theoretical instruction is slow to incorporate new technologies. In addition, Swiss dental labs are very small.

The Association of Swiss Dental Technicians estimates some 1,200 centers, many of which operate with just 1 or 2 people. Therefore, investments in laser melting are carefully considered. Unicim, as a digital production center, acts as a service provider, supplying other laboratories. Right now

I see it as more of an outsourcing topic while we wait for it to take hold in the market.

What is the position of dentists regarding this issue?



Interest is undoubtedly growing, not least because it's impossible to ignore the technical, time-saving and affordability benefits. But we also need to look at the process chain. To prepare the data for manufacturing, the STL format is required. STL data from different scanners can be processed using the CAMbridge or AutoFab Mlab data processing software available from Concept Laser. Nowadays, conventional dental impressions form the basis for CAD data. The accuracy of the data depends on the preciseness of the work performed by the dentist. Higher accuracy is essential. A high-quality intraoral scanner costs dentists today about 20,000 Swiss francs (CHF). If we had complete data migration from the dentist to the dental laboratory, we would be one step further. In the long term, however, that is unavoidable. Quality assurance and documentation needs will make open, manufacturer-independent data transfer an increasingly critical requirement. Especially in terms of affordability, the topic of laser melting is becoming more important.

<u>_contact</u>	<b>laser</b>
<p><b>Concept Laser GmbH</b> An der Zeil 8, 96215 Lichtenfels Germany</p> <p>Tel.: +49 9571 949238 Fax: +49 9571 949249</p> <p><a href="http://www.concept-laser.de">www.concept-laser.de</a></p>	

The editors of laser would like to thank all authors for dedicating their time and efforts to this year's issues.

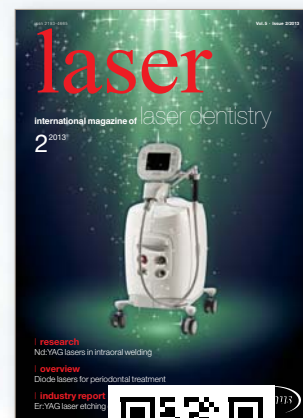
### Issue 1/2013

Dr Jonas de Almeida Rodrigues, Brazil  
 Cristiane Meira Assunção, Brazil  
 Dr Georg Bach, Germany  
 Prof. Dr Reiner Biffar, Germany  
 Prof. Dr Carlo Fornaini, Italy  
 Dr Michael Hopp, Germany  
 Dr Darius Moghtader, Germany  
 Joanna Tatith Pereira, Brazil  
 Dr Avi Reyhanian, Israel  
 Renata Schlesner Oliveira, Brazil



### Issue 2/2013

Dr Ralf Borchers, MSc, Germany  
 Prof. Dr Carlo Fornaini, Italy  
 George Freedman, Canada  
 Dr Shachi Goenka, India  
 Dr Fay Goldstep, Canada  
 Prof. Dr Norbert Gutknecht, Germany  
 Dr Vivek Hegde, India  
 Dr Paresh Jain, India  
 Hans J. Koort, Germany  
 Samah S. Mehani, Egypt  
 Dr Ana Minovska, Bulgaria  
 Laura Navasaityte, Bulgaria  
 Birute Rakauskaitė, Bulgaria  
 Ali M. Saafan, Egypt  
 Dr Sucheta Sathe, India  
 Prof. Dr Georgi Tomov, Bulgaria  
 Dr Naresh Thukral, India  
 Nermin M. Yussif, MSc, Egypt



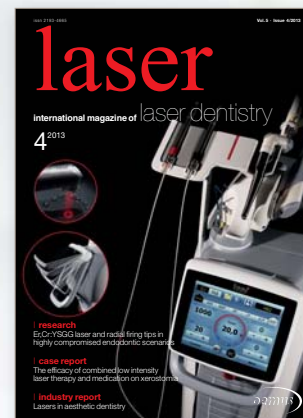
### Issue 3/2013

Dr Glenn A. van As, Canada  
 Dr Georg Bach, Germany  
 José Luis Capote Femenias, Cuba  
 Res. Asst. Dt. Necla Aslı Kocak, Turkey  
 Prof. (Shandong University, China)  
 Dr Frank Liebaug, Germany  
 Dr Darius Moghtader, Germany  
 Giovanni Olivi, Italy  
 Matteo Olivi, Italy  
 Emin Selim Pamuk, Turkey  
 Dr Wariya Panprasit, Thailand  
 Prof. Dr Georgios Romanos, USA  
 Pedro J. Muñoz Sánchez, Cuba  
 Sajee Sattayut, Thailand  
 Prof. Dr Georgi Tomov, Bulgaria  
 Jan Tunér, Sweden  
 Dr Blagovesta Yaneva, Bulgaria  
 Prof. Dr Aslan Yasar Gokbuget, Turkey  
 Dr Anna Maria Yiannikos, Germany/Cyprus  
 Dr Ning Wu, Germany



### Issue 4/2013

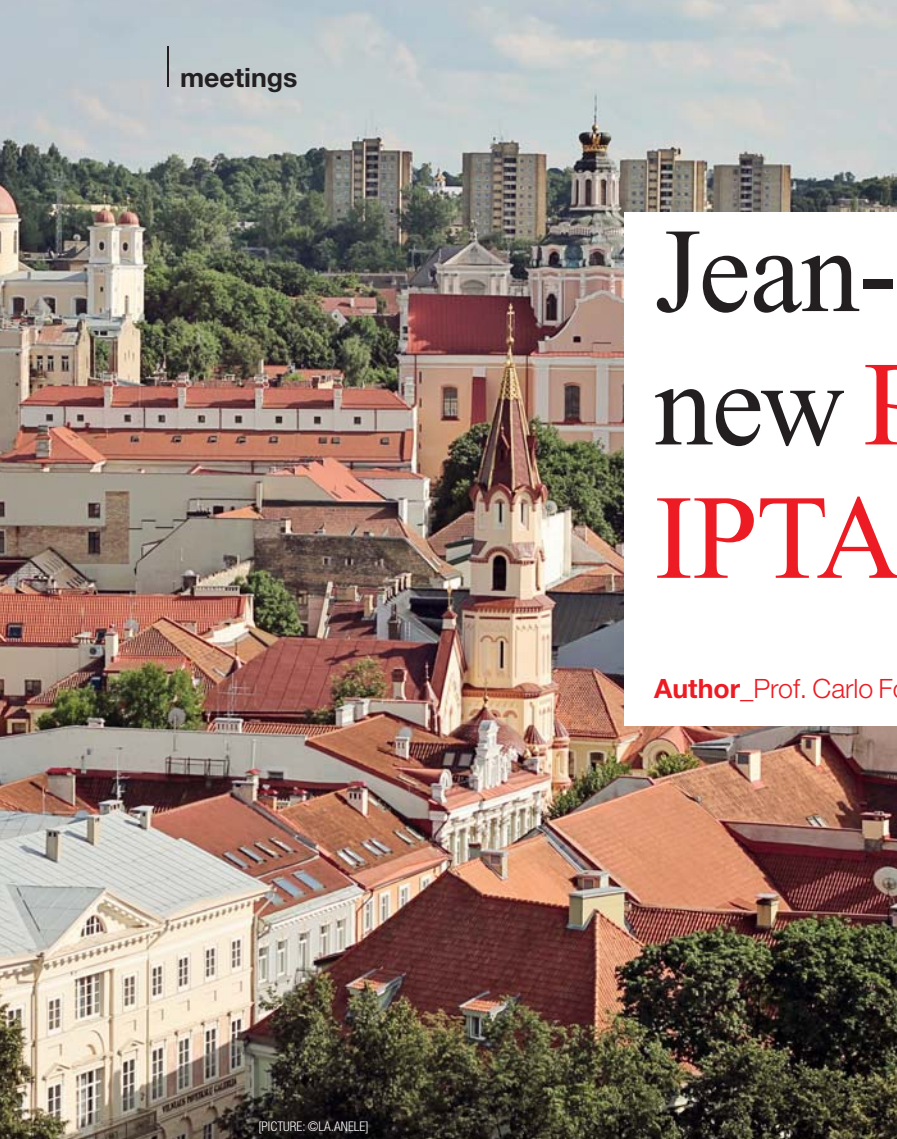
Prof. Carlo Fornaini, Italy  
 Prof. Dr Norbert Gutknecht, Germany  
 Prof. Dr Michael Hopp, Germany  
 Dr Kirpa Johar, India  
 Zafer Kazak, Turkey  
 Hans J. Koort, Germany  
 Dr Ilay Maden, Turkey  
 Özge Erbil Maden, Turkey  
 Miguel Martins, Portugal  
 Prof. Dr D. Gabrić Pandurić, Croatia  
 Assoc. Prof. Dr Sajee Sattayut, Thailand  
 Dr Michael Sultan, UK  
 Dr Sawanya Taboran, Thailand  
 Dr Anna Maria Yiannikos, Germany/Cyprus



become an author  
 for "laser"

Please contact Claudia Jahn  
 ✉ c.jahn@oemus-media.de





[PICTURE © LA ANELE]

# Jean-Paul Rocca new President of IPTA

Author\_Prof. Carlo Fornaini, Italy



Prof. Rocca, new President of IPTA (right), with Prof. Vaitkuviene, Past President (center) and Prof. Oshiro, Treasurer (left).

On the 19 and 20 of September in Vilnius, the capital of Lithuania, the "World Laserology Congress" was celebrated with the participation of the most important scientific societies involved with the utilisation of the laser technology in medicine: ISLSM (International Society for Laser in Surgery and Medicine), IPTA (International Photo-Therapy Association), WFLSMS (World Federation Societies for Laser in Medicine and Surgery), WFLD (World Federation for Laser in Dentistry) and EMDOLA ACADEMY.

The President of the Congress, Prof. Aurelija Vaitkuviene, also President of IPTA, decided to propose a program based on the interaction of physics and medicine in all the specialities and, for these reasons, she invited as speakers people who are among the best experts of the field in the world.

So, Prof. Toshio Oshiro from Japan, General Secretary of WFLSMS and Editor of the journal "Laser Therapy", Prof. Jouzas Vaitkus, President of the Lithuanian Physical Society, Prof. Leonardo Longo from Florence, President of WFLSMS and IALMS, Prof. Juanita Anders from Bethesda University, President Elect of the American Society for Laser in Medicine and Surgery, Prof. Chang Jen Cheng, President of Laser and Photonics Medicine of the Republic of China, Prof. Krishna Rau from India, Past President of

WFLSMS, Prof. Carlo Fornaini from Italy, President Elect of WFLD and Prof. Jean-Paul Rocca from France, Past President of WFLD and Honorary President of EMDOLA Academy, showed to the participants the state-of-the-art of the application of the laser technology in each medical and surgical field by several important lectures.

Among others, lectures were held on the therapy of LLLT on the paresis of facial nerve (Anders), the laser effect on the cerebral palsy (Asagai), the laser treatment of scars (Oshiro), the laser action on the regeneration of the mandibular nerve lesions (Longo), The IntraOral Laser Welding (Fornaini) and the Educational Program in Laserology (Rocca).

During the congress, the assembly of IPTA elected the new president in the person of Prof. Jean Paul Rocca, the director of the TELEO Laboratory of the University of Nice, an expert on the interaction between Er:YAG and hard dental tissues.

Prof. Rocca, in accepting of the new position, announced that the next IPTA Congress will be held in Nice in June 2015, joint to the Emdola Academy Congress. All our good wishes for a good and successful work in the association go to Prof. Rocca and the new Board of IPTA.

# International events

## 2013

### Greater New York Dental Meeting

New York, USA

29 December 2013 to 4 January 2014

[www.gnydm.com](http://www.gnydm.com)

### 2013 Dental Istanbul

Istanbul, Turkey

7–8 December 2013

[www.dentalistanbul.com](http://www.dentalistanbul.com)

### Academy of Osseointegration

#### Annual Meeting 2014

Seattle, WA, USA

6–8 March 2014

[www.osseo.org](http://www.osseo.org)

### WFLD – 5<sup>th</sup> Congress

Paris, France

3–4 July 2013

[www.wfld.info](http://www.wfld.info)

## 2014

### AEEDC Dubai 2014

#### 18<sup>th</sup> UAE International Dental Conference

#### & Arab Dental Exhibition

Dubai, UAE

4–6 February 2014

[www.aeedc.com](http://www.aeedc.com)

### ALD 2014 Academy of Laser Dentistry

Scottsdale, AZ, USA

27 February to 1 March 2014

[www.laserdentistry.org](http://www.laserdentistry.org)

### Pacific Dental Conference 2014

Vancouver, Canada

6–8 March 2014

[www.pdconf.com](http://www.pdconf.com)



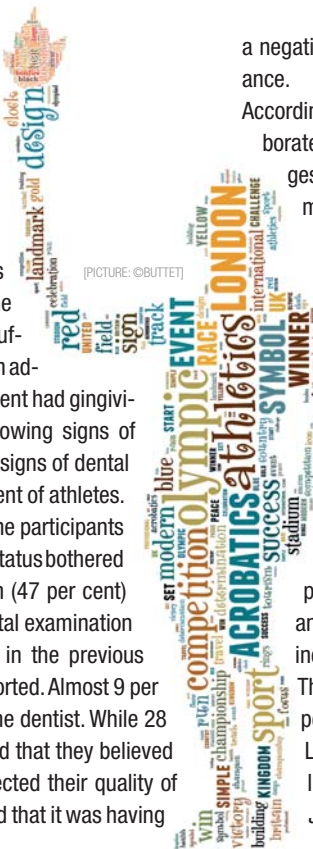## Olympic athletes with Poor oral health

Researchers from the UK have evaluated the oral health status of athletes who took part in the 2012 Olympic Games held in London. Through systematic oral check-ups, the researchers found that 55 per cent of the 302 athletes surveyed suffered from dental caries. In addition, more than 75 per cent had gingivitis, with 15 per cent showing signs of periodontitis. They found signs of dental erosion in about 45 per cent of athletes. Although 42 per cent of the participants said that their oral health status bothered them, nearly half of them (47 per cent) had not undergone a dental examination or professional cleaning in the previous year, the researchers reported. Almost 9 per cent had never been to the dentist. While 28 per cent of athletes stated that they believed that their oral health affected their quality of life, about 18 per cent said that it was having

a negative impact on their training and performance.

According to the researchers, the findings corroborate those of previous studies, which suggested that poor oral health in sportsmen might be a result of frequent carbohydrate intake, a reduced immune function owing to intensive training, and a lack of awareness about the link between oral health, overall health and physical performance.

The study was conducted by researchers at University College London's Eastman Dental Institute at the dental clinic in the London 2012 athletes' village. The study population comprised athletes from Africa, the Americas and Europe competing in 25 different sports, including track and field, boxing and hockey. The study, titled "Oral health and impact on performance of athletes participating in the London 2012 Olympic Games", was published online on 24 September in the *British Journal of Sport Medicine* ahead of print.



## Predictors of satisfaction with Aesthetic dental work

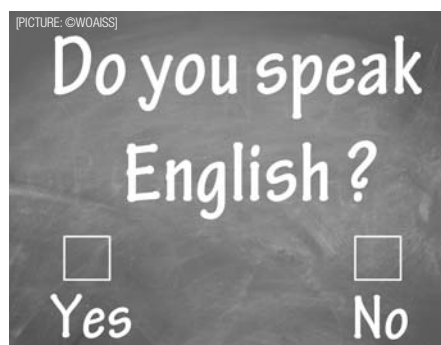A new study conducted by researchers at the Department of Dental Public Health at King's College London has found that some dental patients may need to consult a psychologist before undergoing treatment. In a study with 60 participants, the researchers found that higher satisfaction with appearance before dental aesthetic treatment affected patients' satisfaction after treatment significantly.



For the study, all participants were asked to assess satisfaction with their appearance before and after dental work according to a predefined scale. Additionally, they completed a personality test prior to the procedure. Among other findings, the researchers found that participants who were most satisfied with their appearance before receiving dental aesthetic treatment were also the happiest patients after treatment. On the other hand, neuroticism seemed to persist after treatment in those patients who were rather dissatisfied before.

"We found that it is in patients' and dentists' interest to ensure that patients receiving aesthetic dental work start from as high a point of satisfaction with their current appearance as possible. This will enhance the chances that they will be satisfied with the result of the treatment," the researchers concluded. The findings were presented on Wednesday at the British Psychological Society's Division of Health Psychology Annual Conference, which was held from 11 to 13 September in Brighton.

## Foreign dentists Face language tests in UK



The UK Department of Health announced its plans to introduce language tests for European medical professionals wishing to work in the UK. The new regulation will give the General Medical Council (GMC) the power to impose checks where concerns arise about a doctor's English language competence.

According to the department, the new proposals are designed to complement and strengthen the existing language controls imposed on medical staff through the Responsible Officers Regulations, Performers Lists Regulations and other checks undertaken at a local level, which were introduced in April this year.

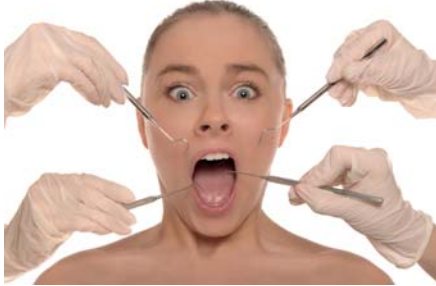Health Minister Dr Dan Poulter explained that the GMC will be entitled to carry out assessments before allowing European doctors from outside the UK to treat patients in a hospital or general practice. By carrying out tests at a national level, the minister hopes to prevent doctors who do not have the necessary knowledge of English from treating patients. To be accepted on a centrally held list, general practitioners will have to demonstrate their ability to communicate in English. The new rules are expected to come into effect in 2014.



## Dentophobia

# More common in women than men

[PICTURE: ©ZAMETALOV]



Dentophobia is equally common in both men and women. However, a new study has found that the level of disgust they experience with regard to dental treatment may differ significantly. In the study, 36 individuals with dentophobia (18 men and 18 women) and 36 non-dentophobic controls were asked to rate their arousal, disgust and fear while looking at images of dental treatment scenes and images depicting neutral scenes. Simultaneously, their heart rate and the activity of the musculus levator labii, a muscle used in pro-

typical facial disgust expression, producing nose wrinkles and upper lip retraction, were recorded electronically. Overall, male and female participants did not differ in their self-ratings. However, there were significant differences in facial expressions. According to the researchers, only dentophobic women showed enhanced disgust-related facial activity, indicating that targeting of disorder-specific disgust might be of great importance in the therapy of dentophobic women.

Although dentophobic men perceived dental treatment scenes as equally disgusting as did women, they displayed significantly lower disgust-related facial activity. However, the researchers suggested that male participants might have been more successful in inhibiting behavioural reactions. The study, titled "Can you read my pokerface? A study on sex differences in dentophobia", was published online on 12 September in the *European Journal of Oral Sciences* and will appear in the October issue. It was conducted at the University of Graz.

## Poor dental health

# May lead to Alzheimer's

People with poor oral hygiene or gum disease may be at a greater risk of developing Alzheimer's disease, a study led by the University of Central Lancashire's (UCLan) School of Medicine and Dentistry has found. For their study, the researchers examined samples from the donated brains of ten peo-

ple without dementia and ten people with dementia. The research found the presence of products from *Porphyromonas gingivalis* in the brains of dementia patients.

The research benefited from donated brain samples provided by Brains for Dementia Research, a brain donation scheme supported by Alzheimer's Research UK and Alzheimer's Society. Finding *P. gingivalis* in the brains of dementia sufferers is significant, as its presence in the brains of Alzheimer's disease patients has not been documented previously and the finding adds to a growing body of evidence that suggests an association between poor oral health and dementia.

These published research findings from human brain specimens are further supported by recent unpublished research on periodontal disease from the same group using animal models, which was carried out in collaboration with the University of Florida. This animal work has confirmed that *P. gingivalis* in the mouth finds its way to the brain once periodontal disease has become established.

## Chewing popcorn may disturb


# Moviegoers' perception of commercials

Psychologists from Germany have suggested that eating popcorn disrupts the way people process and remember brand names. In a recently published study, participants were invited to a movie theatre and were shown a block of foreign commercials prior to the film. Half of the participants were given popcorn to eat, while



the other participants chewed gum or ate a single sugar cube. When the participants were presented with images of products one week after the cinema session, those who had eaten the sugar cubes exhibited higher preference and physiological responses for the brands advertised. In contrast, the participants who had consumed popcorn or gum during the commercials showed no evidence of advertising effects, the researchers said. According to researchers from the University of Cologne, the advertised products were less familiar to the participants owing to the fact that their mouth was obstructed when they were watching the commercials. Prior studies have shown that subvocal pronunciation, a covert mechanism of the mouth, is very important to the perception of information about new brands. The researchers said that each time a person encounters a new name the lips and the tongue automatically simulate the pronunciation of the name. Because they were chewing, the participants could not internally train the articulation of the brands' names.

The researchers concluded that advertising might remain unsuccessful in situations involving oral interference, such as snacking or talking. The study, titled "Popcorn in the cinema: Oral interference sabotages advertising effects", was published online on 29 September in the *Journal of Consumer Psychology* ahead of print.



[PICTURE: ©MYPKCIK]

# laser

international magazine of laser dentistry



#### Publisher

Torsten R. Oemus  
[oemus@oemus-media.de](mailto:oemus@oemus-media.de)

#### CEO

Ingolf Döbbecke  
[doebbecke@oemus-media.de](mailto:doebbecke@oemus-media.de)

#### Members of the Board

Jürgen Isbaner  
[isbaner@oemus-media.de](mailto:isbaner@oemus-media.de)

Lutz V. Hiller  
[hiller@oemus-media.de](mailto:hiller@oemus-media.de)

#### Editor in Chief

Norbert Gutknecht  
[ngutknecht@ukaachen.de](mailto:ngutknecht@ukaachen.de)

#### Coeditors in Chief

Samir Nammour  
Jean Paul Rocca

#### Managing Editors

Georg Bach  
Leon Vanweersch

#### Division Editors

Matthias Frentzen  
*European Division*

George Romanos  
*North America Division*

Carlos de Paula Eduardo  
*South America Division*

Toni Zeinoun  
*Middle East & Africa Division*

Loh Hong Sai  
*Asia & Pacific Division*

#### Senior Editors

Aldo Brugneira Junior  
Yoshimitsu Abiko  
Lynn Powell  
John Featherstone  
Adam Stabholz  
Jan Tuner  
Anton Sculean

#### Editorial Board

Marcia Martins Marques, Leonardo Silberman, Emna Ibrahim, Igor Cernavin, Daniel Heyselaer, Roeland de Moor, Julia Kamenova, T. Dostalova, Christliebe Pasini, Peter Steen Hansen, Aisha Sultan, Ahmed A Hassan, Marita Luomanen, Patrick Maher, Marie France Bertrand, Frederic Gaultier, Antonis Kallis, Dimitris Strakas, Kenneth Luk, Mukul Jain, Reza Fekrazad, Sharonit Sahar-Helft, Lajos Gaspar, Paolo Vescovi, Marina Vitale, Carlo Fornaini, Kenji Yoshida, Hideaki Suda, Ki-Suk Kim, Liang Ling Seow, Shaymant Singh Makhan, Enrique Trevino, Ahmed Kabir, Blanca de Grande, José Correia de Campos, Carmen Todea, Saleh Ghabban Stephen Hsu, Antoni Espana Tost, Josep Arnabat, Ahmed Abdullah, Boris Gaspirc, Peter Fahlstedt, Claes Larsson, Michel Vock, Hsin-Cheng Liu, Sajee Sattayut, Ferda Tasar, Sevil Gurgan, Cem Sener, Christopher Mercer, Valentin Preve, Ali Obeidi, Anna-Maria Yannikou, Suchetan Pradhan, Ryan Seto, Joyce Fong, Ingmar Ingenegeren, Peter Klee- mann, Iris Brader, Masoud Mojahedi, Gerd Volland, Gabriele Schindler, Ralf Borchers, Stefan Grümer, Joachim Schiffer, Detlef Klotz, Herbert Deppe, Friedrich Lampert, Jörg Meister, Rene Franzen, Andreas Braun, Sabine Sennhenn-Kirchner, Siegfried Jänicke, Olaf Oberhofer, Thorsten Kleinert

#### Editorial Office

Georg Isbaner  
[g.isbaner@oemus-media.de](mailto:g.isbaner@oemus-media.de)

Claudia Jahn  
[c.jahn@oemus-media.de](mailto:c.jahn@oemus-media.de)

#### Executive Producer

Gernot Meyer  
[meyer@oemus-media.de](mailto:meyer@oemus-media.de)

#### Designer

Sarah Fuhrmann  
[s.fuhrmann@oemus-media.de](mailto:s.fuhrmann@oemus-media.de)

#### Customer Service

Marius Mezger  
[m.mezger@oemus-media.de](mailto:m.mezger@oemus-media.de)

#### Published by

OEMUS MEDIA AG  
Holbeinstraße 29  
04229 Leipzig, Germany  
Tel.: +49 341 48474-0  
Fax: +49 341 48474-290  
[kontakt@oemus-media.de](mailto:kontakt@oemus-media.de)  
[www.oemus.com](http://www.oemus.com)

#### Printed by

Löhnert Druck  
Handelsstraße 12  
04420 Markranstädt, Germany

#### laser

international magazine of laser dentistry  
is published in cooperation with the World  
Federation for Laser Dentistry (WFLD).

#### WFLD Headquarters

University of Aachen Medical Faculty  
Clinic of Conservative Dentistry  
Pauwelsstr. 30, 52074 Aachen, Germany  
Tel.: +49 241 808964  
Fax: +49 241 803389644  
[ngutknecht@ukaachen.de](mailto:ngutknecht@ukaachen.de)  
[www.wfld-org.info](http://www.wfld-org.info)

#### Copyright Regulations

\_laser international magazine of laser dentistry is published by OEMUS MEDIA AG and will appear in 2013 with one issue every quarter. The magazine and all articles and illustrations therein are protected by copyright. Any utilization without the prior consent of editor and publisher is inadmissible and liable to prosecution. This applies in particular to duplicate copies, translations, microfilms, and storage and processing in electronic systems.

Reproductions, including extracts, may only be made with the permission of the publisher. Given no statement to the contrary, any submissions to the editorial department are understood to be in agreement with a full or partial publishing of said submission. The editorial department reserves the right to check all submitted articles for formal errors and factual authority, and to make amendments if necessary. No responsibility shall be taken for unsolicited books and manuscripts. Articles bearing symbols other than that of the editorial department, or which are distinguished by the name of the author, represent the opinion of the afore-mentioned, and do not have to comply with the views of Oemus Media AG. Responsibility for such articles shall be borne by the author. Responsibility for advertisements and other specially labeled items shall not be borne by the editorial department. Likewise, no responsibility shall be assumed for information published about associations, companies and commercial markets. All cases of consequential liability arising from inaccurate or faulty representation are excluded. General terms and conditions apply, legal venue is Leipzig, Germany.

# laser

international magazine of laser dentistry



 **Subscribe now!**

**You can also subscribe via  
[www.oemus.com/abo](http://www.oemus.com/abo)**

I would like to subscribe to **laser** international magazine of laser dentistry (4 issues per year) for € 44 including shipping and VAT for German customers, € 46 including shipping and VAT for customers outside Germany, unless a written cancellation is sent within 14 days of the receipt of the trial subscription. The subscription will be renewed automatically every year until a written cancellation is sent to OEMUS MEDIA AG, Holbeinstr. 29, 04229 Leipzig, Germany, six weeks prior to the renewal date.

▶ **Reply** via Fax +49 341 48474-290 to OEMUS MEDIA AG or per E-mail to [grasse@oemus-media.de](mailto:grasse@oemus-media.de)

Last Name, First Name	
Company	
Street	
ZIP/City/County	
E-mail	Signature

Notice of revocation: I am able to revoke the subscription within 14 days after my order by sending a written cancellation to OEMUS MEDIA AG, Holbeinstr. 29, 04229 Leipzig, Germany.

Signature
-----------





The first digitally controlled  
dental laser handpiece

## X-Runner

- instantly adjustable spot size and shape
- precise coverage of large areas
- lightweight, ergonomic design
- for Fotona LightWalker AT laser systems

